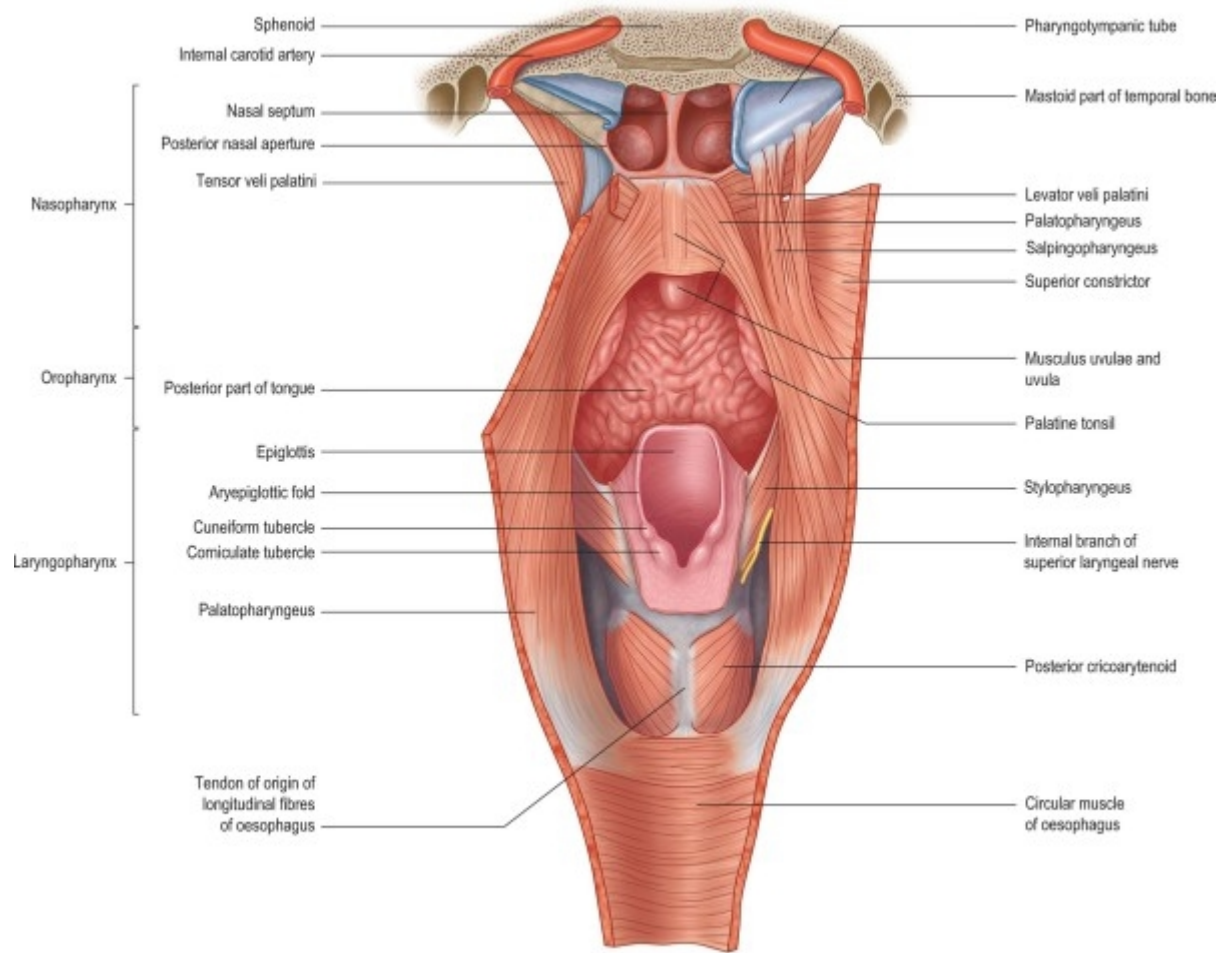
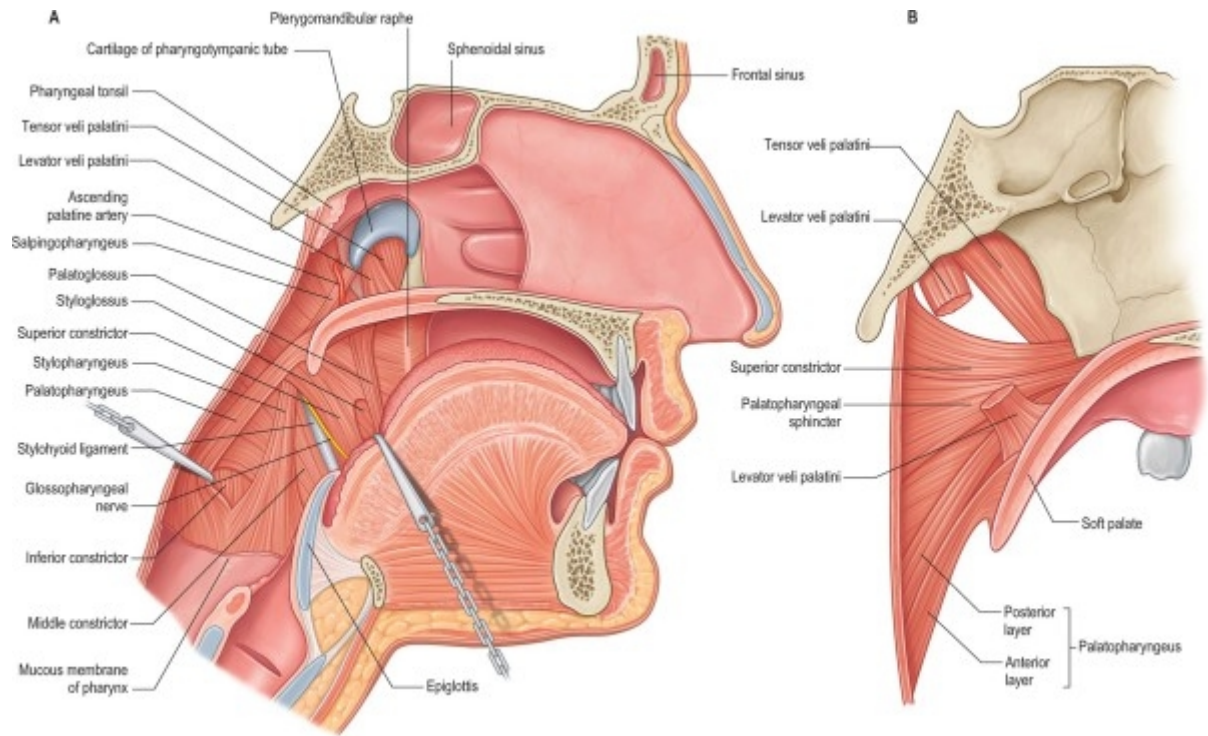


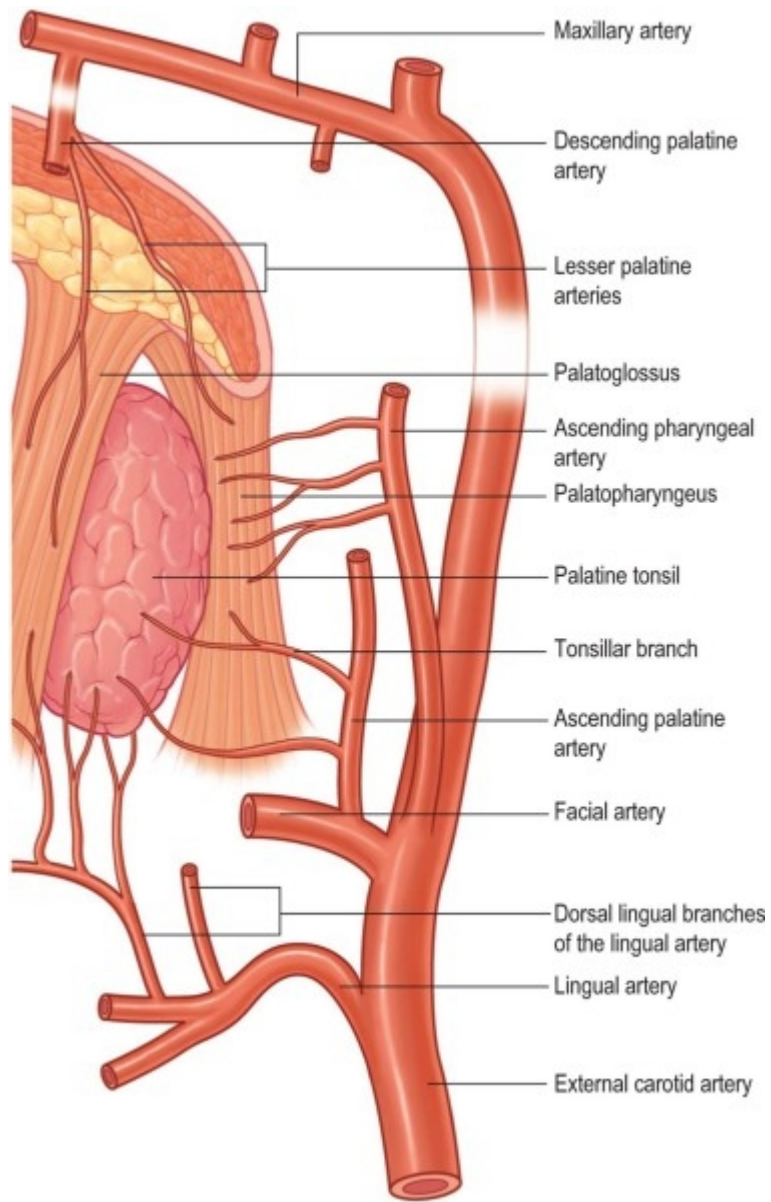
# Posterior View of Pharynx 33.1



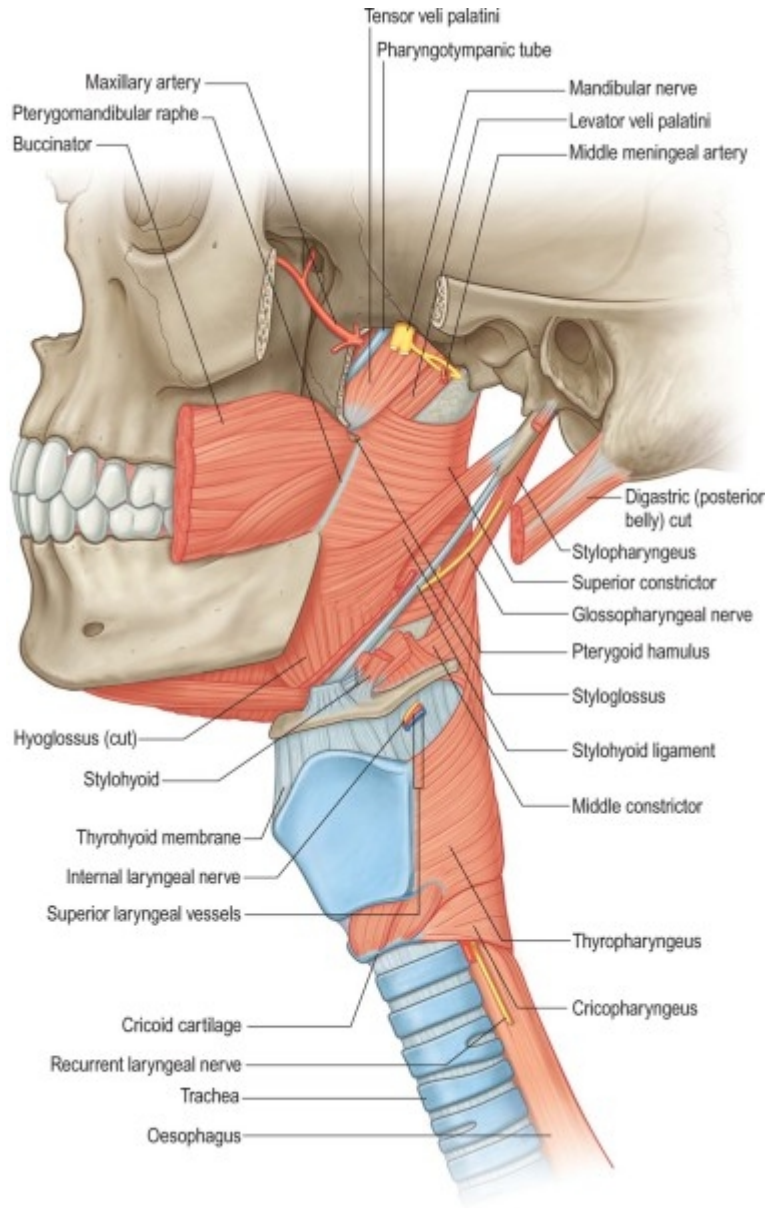
# Interior of the Pharynx 33.4



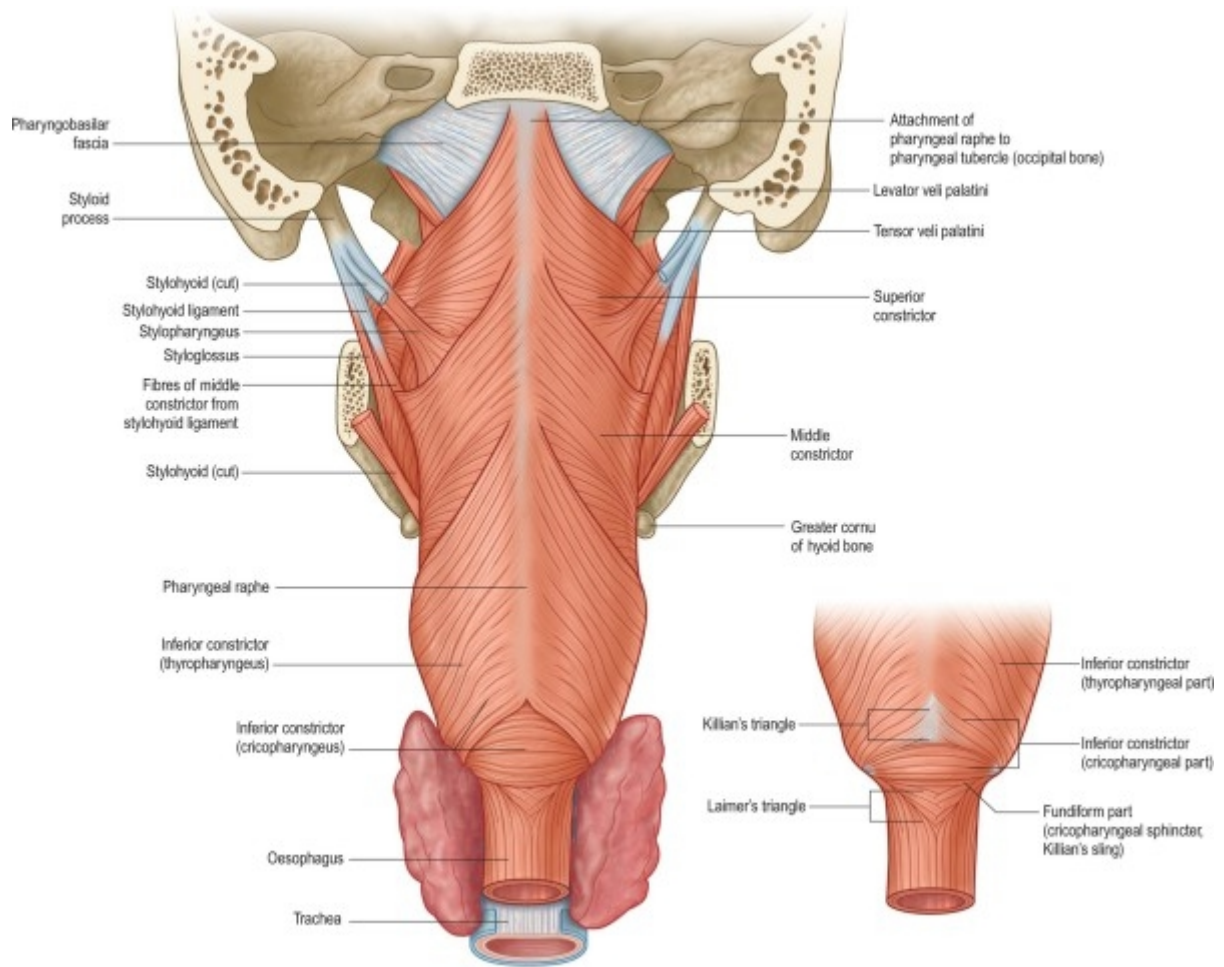
# Arterial Supply to Palatine Tonsil 33.6



# Lateral View of Pharynx 33.7



# Posterior View of Pharynx 33.9





# Choanae – Posterior View 32.4

