

TWiki > Main

r3 - 14 Oct 2007 - 21:55:25 - LorenEvey

Web > HeadNeckLectures > ParotidRegionLaboratoryIdentifications

This site has been visited 7641 times since July 10, 2007

Parotid Region - Laboratory Identifications

Temporomandibular Joint and Parotid Region

- Mastoid process
- Styloid process
- Stylomastoid foramen
- External acoustic meatus
- Postglenoid tubercle
- Mandibular fossa
- Articular tubercle
- Condyle
- Mandibular notch
- Masseteric artery
- Masseteric nerve
- Coronoid process
- Articular capsule
- Superior synovial cavity
- Articular Disk
- Inferior synovial cavity
- Superior head of lateral pterygoid
- Inferior head of lateral pterygoid
- Posterior fibers of temporalis
- Anterior fibers of temporalis
- Facial nerve
- Auriculotemporal nerve
- Communicating branch (parasympathetics)
- Posterior belly digastric
- Stylohyoid muscle
- Lesser occipital nerve
- Great auricular nerve
- Parotid Gland

Mandible

- condyle - site of insertion for inferior head lateral pterygoid muscle
- neck - anterior to external auditory canal
- coronoid process - insertion of temporalis muscle
- mandibular notch - transmits masseteric artery and nerve to masseter muscle
- ramus - lateral boarder of infratemporal fossa, retromandibular vein, maxillary artery, parotid gland
- angle - near level of lingula (medial surface)
- body - most commonly broken bone in males, fracture puts inferior alveolar nerve and artery at risk
- inferior alveolar process - base of teeth

- mandibular foramen - transmits inferior alveolar nerve and artery into mandible, inferior to lingula
- lingula - site of attachment of sphenomandibular ligament
- digastric fossa - origin of anterior belly of digastric muscle
- superior and inferior mental spine - origin of genioglossus and geniohyoid muscles
- sphenomandibular ligament - from spine of sphenoid to lingula, limits depression of the mandible
- mental foramen - transmits mental nerve and artery (continuation of inferior alveolar nerve)
- inferior alveolar nerve and artery - provides the inferior dental plexus
- inferior dental plexus
- temporalis muscle - arises from temporal fossa, medial to zygomatic arch, inserts on coronoid process and anterior ramus
- masseter muscle - arises from zygomatic arch, inserts on lateral body and angle of mandible
- medial pterygoid muscle - originates from medial aspect of lateral pterygoid plate, inserts on medial body
- mental nerve and artery

 [Top](#)


Comments

 [Top](#)

-- [LorenEvey](#) - 15 Oct 2007

Access Control:

- Set DENYTOPICVIEW =

Copyright © by the contributing authors. All material on this collaboration platform is the property of the contributing authors.  TWiki

Ideas, requests, problems regarding TWiki? [Send feedback](#)

Temporal Fossa, Temporomandibular Joint, and Infratemporal Fossa - Laboratory Identifications

Abbreviations for this Identification List

- PTF = Pterygopalatine Fossa.
- IFTF = Infratemporal Fossa
- LSPN = Lesser Superficial Petrosal Nerve
- MCF = middle cranial fossa

Boundaries for Infratemporal Fossa - Skull Landmarks

1. anterior - posterior aspect of maxilla
2. posterior - styloid process
3. superior - infratemporal crest
4. inferior - body of mandible
5. medial - pterygoid plate (pterygo maxillary fissure)
6. lateral - ramus of mandible

Identifications

1. Zygomatic process temporal bone - forms suture with zygoma
2. Mastoid process - attachment of SCM, splenius capitus, longus capitus
3. External auditory meatus
4. Styloid process - site of origin for three mm having three different innervation, stylohyoid ligament
5. Petrotympanic fissure - medial to mandibular fossa, chorda tympani branch of facial
6. Lateral pterygoid plate - medial boundary of IFTF, site of attachment of two muscles of mastication
7. Maxilla - forms anterior boundary of IFTF
8. Zygoma - contributes to zygomatic arch
9. Hamulus of medial pterygoid plate - pulley for tendon of tensor veli palatini
10. Greater wing of sphenoid bone - part of roof of IFTF, pterion, foramen ovale, foramen spinosum
11. Inferior orbital fissure - transmits infraorbital a. (IFTF) and infraorbital n. (PTF)
12. Pterygomaxillary fissure - medial wall of IFTF, communication between IFTF and PTF
13. Pterygopalatine fossa - communicates with IFTF, orbit, nasal cavity, oral cavity, nasopharynx, cavernous sinus (MCF), MCF
14. Foramen spinosum - middle meningeal a., sphenomandibular lig, LSPN, between MCF and IFTF
15. Foramen ovale - mandibular division of trigeminal n., emissary v. (pterygoid plexus to cavernous sinus), LSPN, between MCF and IFTF
16. Sphenopalatine foramen - medial wall of PTF, between PTF and nasal cavity, transmits terminal branches maxillary a, branches of V2
17. External carotid artery - terminating in maxillary a. and superficial temporal a.
18. Superficial temporal artery - giving off transverse facial a., anterior to external auditory meatus, temporal fossa

19. Maxillary artery - posterior to neck of mandible
20. Deep auricular artery - branch off maxillary a. toward base of external auditory meatus
21. Inferior alveolar artery - branch of maxillary a., entering mandibular f.
22. Middle meningeal artery - branch of maxillary a., entering foramen spinosum, surrounded by split of auriculotemporal n.
23. Deep temporal arteries - deep to temporalis, temporal fossa, branches of maxillary in IFTF
24. Buccal artery - branch of maxillary a., crossing lateral surface of medial pterygoid
25. Posterior superior alveolar artery - entering foramen on posterior maxilla
26. Infraorbital artery - branch of maxillary a., entering inferior orbital fissure
27. Artery of maxillary nerve - branch of maxillary a., through foramen rotundum
28. Artery of pterygoid canal - branch of maxillary a., through pterygoid canal
29. Pharyngeal artery - branch of maxillary a. through palatovaginal canal
30. Greater and lesser palatine arteries - leaving floor of pterygopalatine fossa, at hard and soft palate
31. Lateral posterior nasal arteries - terminal branches of maxillary a., through sphenopalatine foramen, superior, middle, inferior
32. Mandibular nerve - at foramen ovale
33. Auriculotemporal nerve - anterior to external auditory meatus
34. Inferior alveolar nerve - entering IFTF from PTF, enters foramen on posterior maxilla
35. Lingual nerve - lateral surface of medial pterygoid muscle
36. Buccal nerve - lateral surface of medial pterygoid muscle, piercing the buccinator
37. Chorda tympani nerve (CN VII) - petrotympanic fissure, joining with the lingual n., functional components
38. Maxillary nerve - roof of pterygopalatine fossa
39. Posterior superior alveolar nerve - entering infratemporal fossa from pterygopalatine fossa
40. Infraorbital nerve - continuation of maxillary n. into the orbit, inferior orbital fissure, roof of PTF
41. Mandibular Foramen - transmits inferior alveolar n. a., adjacent to lingula, dental anesthesia
42. Facial Nerve - entering parotid region from stylomastoid foramen
43. Communicating branch - parasympathetics, leaving auriculotemporal n. to join with branches of facial n.

 [Top](#)


Comments

 [Top](#)

-- [LorenEvey](#) - 15 Oct 2007

 **Access Control:**

- Set DENYTOPICVIEW =

Copyright © by the contributing authors. All material on this collaboration platform is the property of the contributing authors.  **TWiki**

Ideas, requests, problems regarding TWiki? [Send feedback](#)

Temporal Fossa, Temporomandibular Joint, and Infratemporal Fossa - Learning Objectives and Review Questions

Essay

1. Discuss the temporomandibular joint. Include relationships, fascial specializations, vascularization, innervation, muscles and movements, and lymphatic drainage.
2. Discuss the infratemporal fossa. Include boundaries, relationships, fascial specializations, vascularization, innervation, lymphatic drainage, and nerve injury.

Short Answer

1. Articular disk
2. Chorda tympani
3. Pterygomaxillary fissure
4. Styloid Process
5. Lesser superficial petrosal nerve
6. Otic ganglion
7. Lateral pterygoid plate
8. Maxillary artery
9. Sphenomandibular ligament
10. Pterygomandibular raphe

True/False

1. The lesser superficial petrosal nerve is part of a somatic plexus whereas the buccal nerve is part of an autonomic trunk.
2. The masseteric nerve passes through the mandibular notch.
3. The posterior superior alveolar nerve branches from the maxillary nerve within the pterygopalatine fossa and enters the infratemporal fossa through the pterygomaxillary fissure.
4. The buccal nerve passes the lateral aspect of the masseter muscle.
5. The chorda tympani joins onto the inferior alveolar nerve before distributing to the anterior 2/3 of the tongue.
6. Postganglionic fibers from the otic ganglion join onto; first the chorda tympani, and then the lingual nerve.
7. A lesion of the chorda tympani within the infratemporal fossa is expected to decrease sensitivity of touch to the posterior 1/3 of the tongue as well as decrease lacrimation.
8. A lesion of the lingual nerve within the floor of the mouth is expected to disrupt both taste and touch to the anterior 2/3 of the tongue.
9. The mouth is apt to be stuck open if the condyle of the mandible slips forward to the articular tubercle.
10. The left body of the mandible is one of the most commonly broken bones in males.
11. The inferior alveolar nerve contributes to the inferior dental plexus and then continues onto the face as the mental nerve.

12. The nerve to the mylohyoid conveys GSE fibers to the mylohyoid muscle and SVE fibers to the anterior belly of the digastric.
13. The buccal nerve conveys SVE and GSA fibers to the buccinator muscle.
14. The inferior alveolar nerve encircles the middle meningeal artery.
15. The posterior superior alveolar artery does not enter the pterygopalatine fossa despite that the nerve of the same name is within this fossa.
16. The medial pterygoid muscle arises from the medial pterygoid plate whereas the lateral pterygoid muscle arises from the lateral pterygoid plate.
17. The hamulus is an inferior extension of the lateral pterygoid plate.
18. The maxillary artery passes from the infratemporal fossa to the pterygopalatine fossa whereas the maxillary nerve does not enter the infratemporal fossa.
19. The lingula of the mandible is a site of attachment for the pterygomandibular raphe.
20. The hamulus of the medial pterygoid plate is a site of attachment for the sphenomandibular ligament.
21. The groove for the mylohyoid nerve proceeds inferior and anterior from the mandibular foramen
22. A lesion of the lesser superficial petrosal nerve is expected to cause ipsilateral salivatory deficits.
23. A lesion of the lingual nerve at the foramen ovale is expected to disrupt touch (GSA) but not taste (SVA) to the anterior 2/3 of the tongue.
24. A lesion of the auriculotemporal nerve just medial to the neck of the mandible is expected to cause a salivatory deficit.
25. The sympathetic root of the otic ganglion is derived from the external carotid plexus (middle meningeal plexus).

 [Top](#)


Comments

 [Top](#)

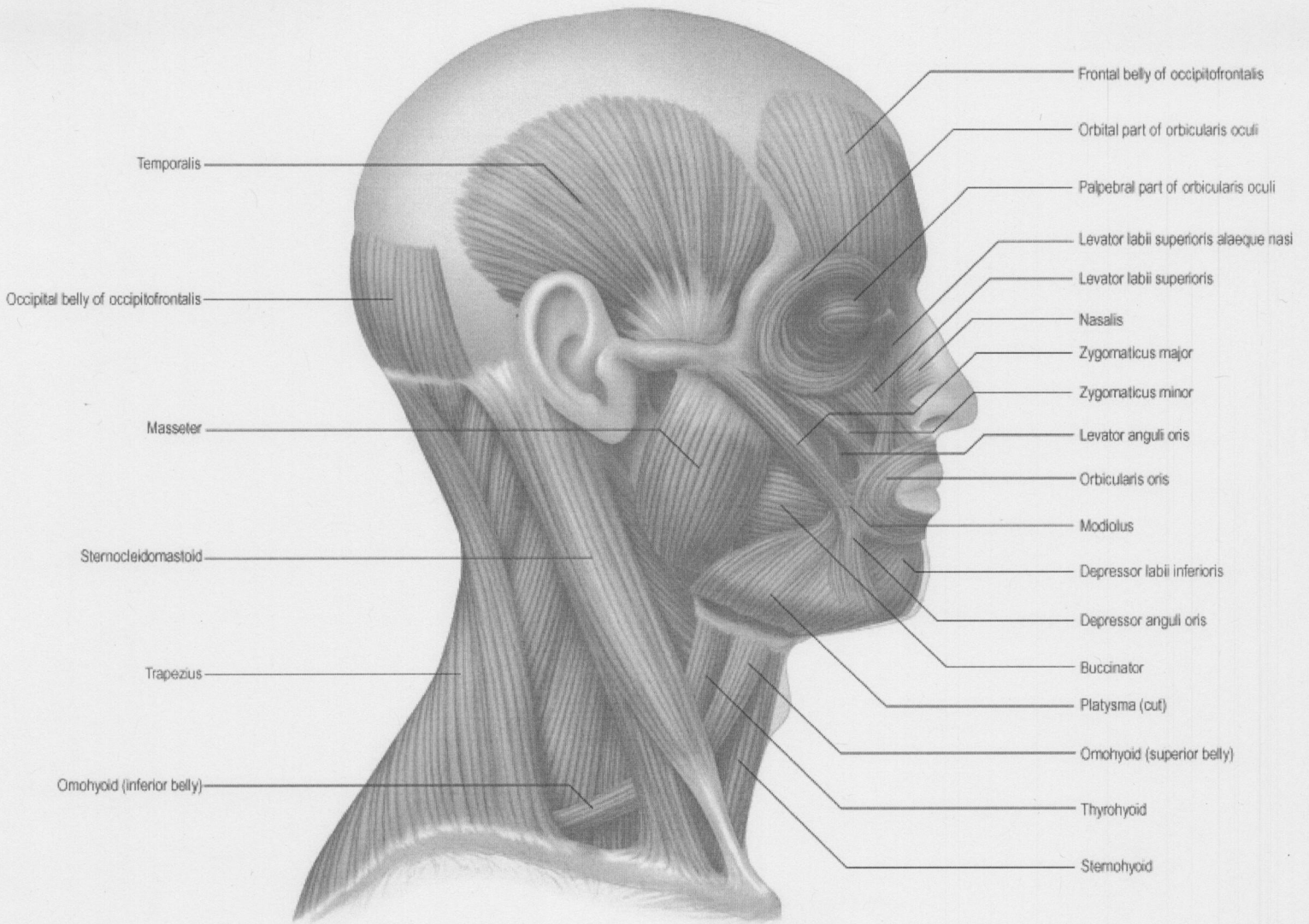
-- [LorenEvey](#) - 15 Oct 2007

Access Control:

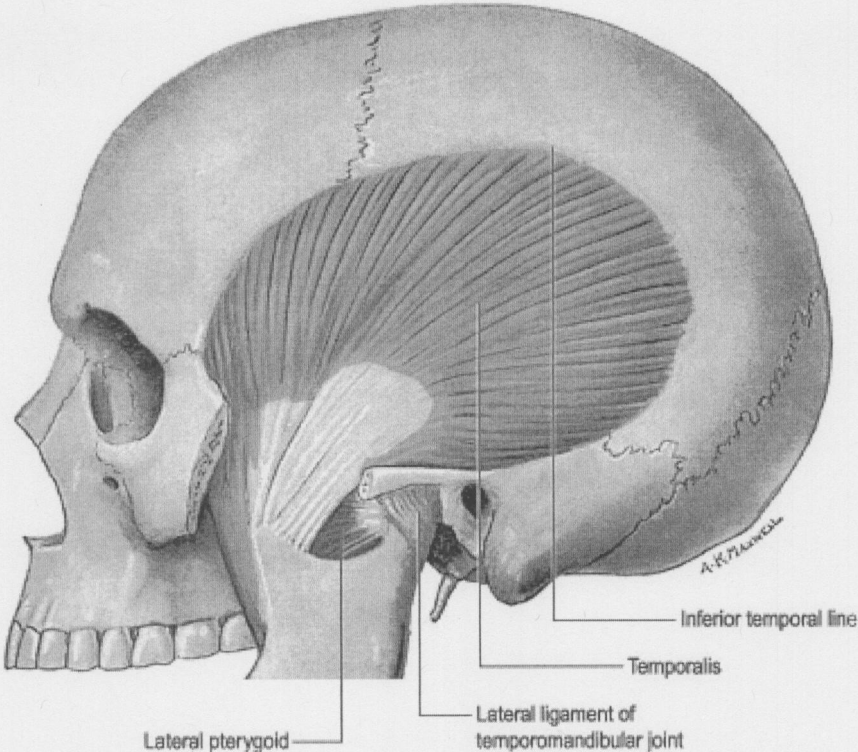
- Set DENYTOPICVIEW =

Copyright © by the contributing authors. All material on this collaboration platform is the property of the contributing  **TWiki** authors.
Ideas, requests, problems regarding TWiki? [Send feedback](#)

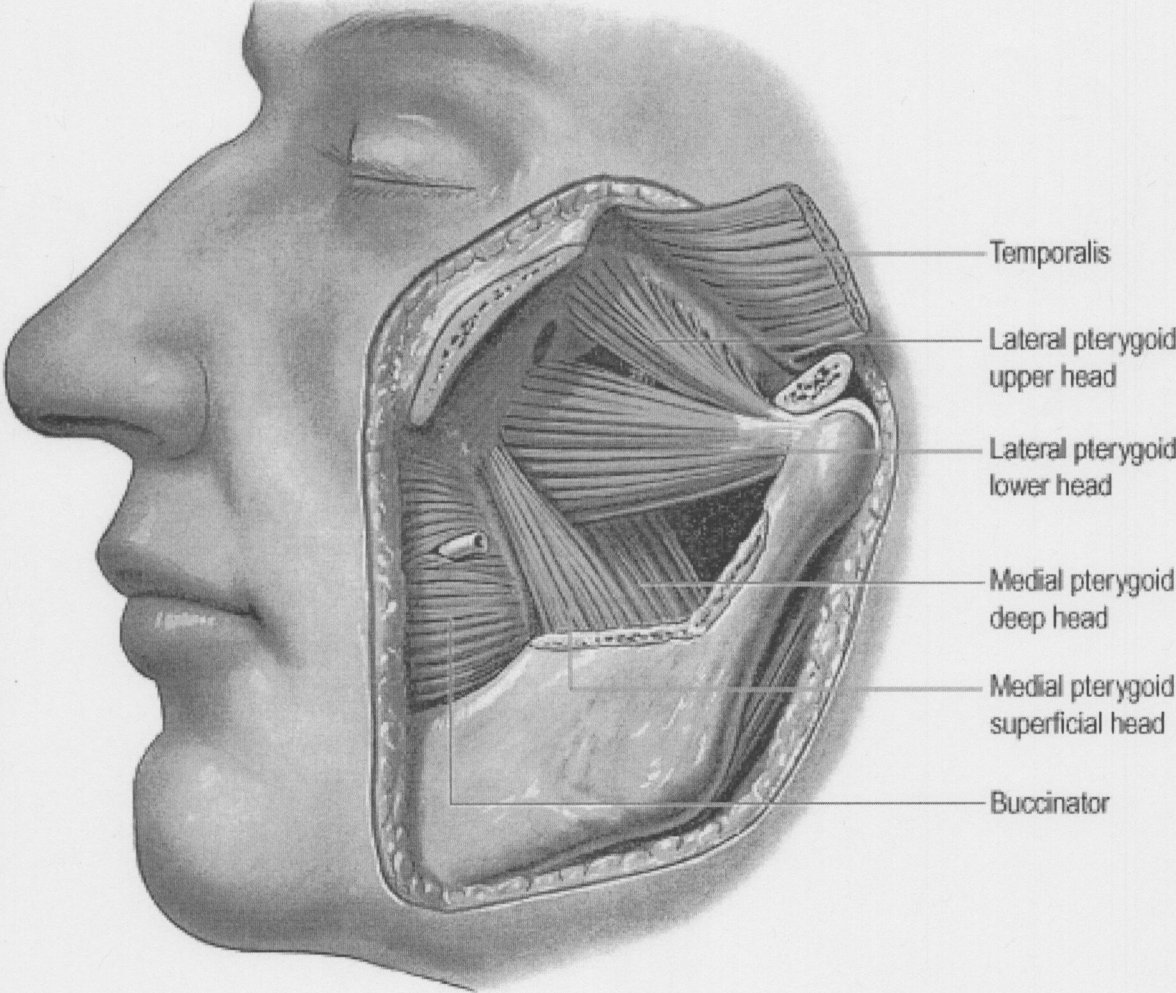
Gray's 29.5. Superficial Muscles of Head and Neck



Gray's 30.2 & 30.3. Temporalis and Pterygoid Muscles

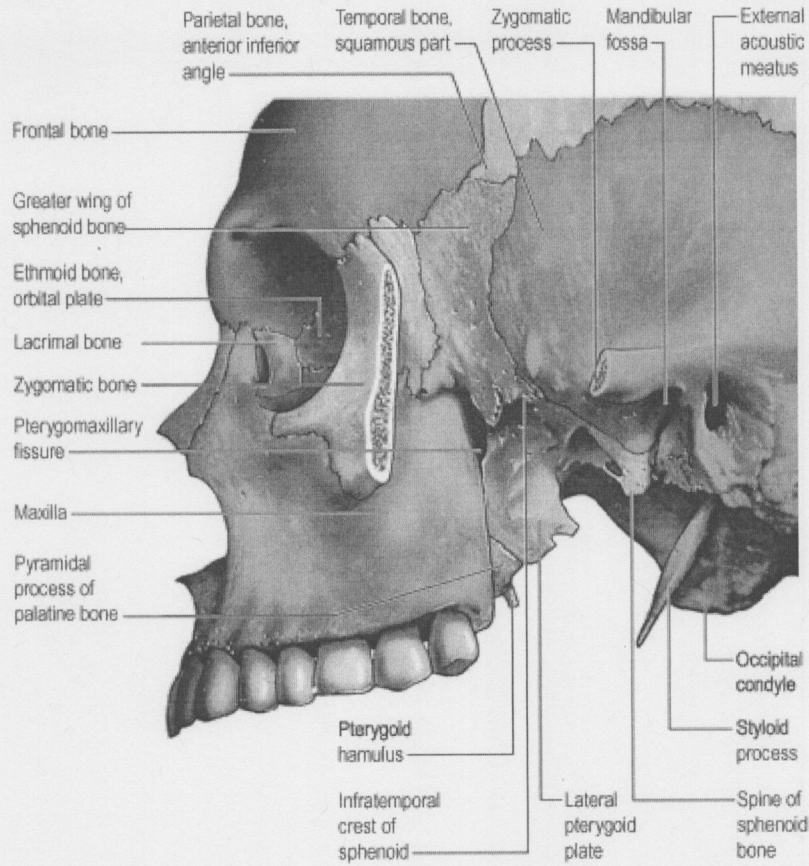


© Elsevier Ltd 2005. Standing: Gray's Anatomy 39e

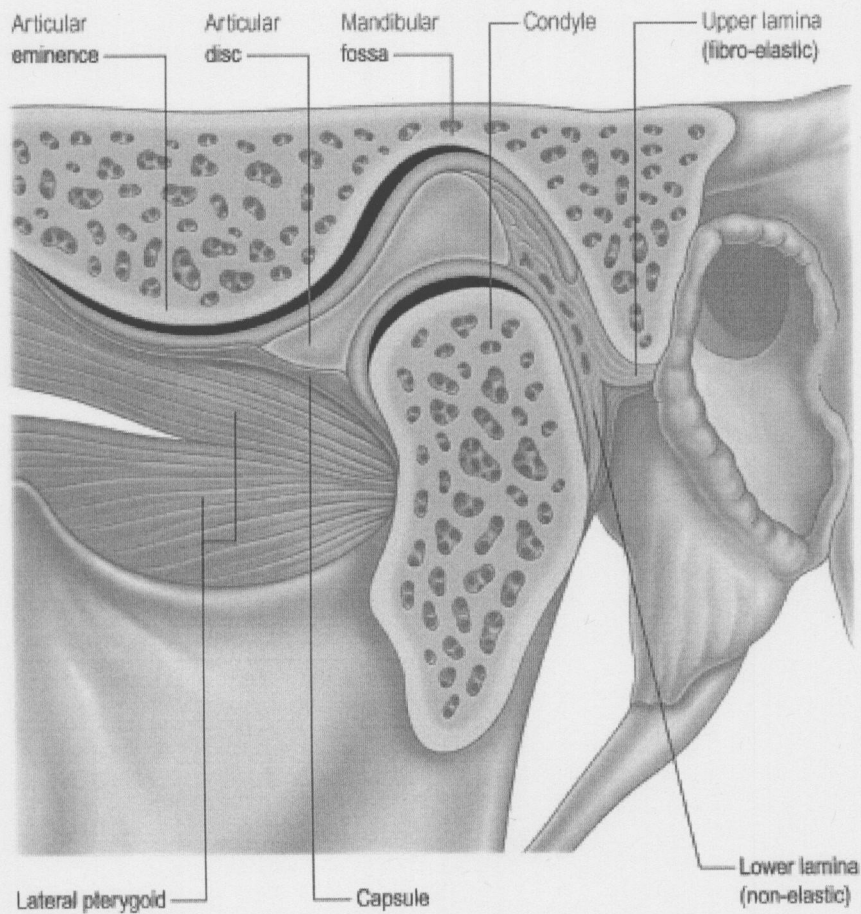


© Elsevier Ltd 2005. Standing: Gray's Anatomy 39e

Gray's 30.1 & 30.10. Infratemporal Fossa and Temporotemporal Joint

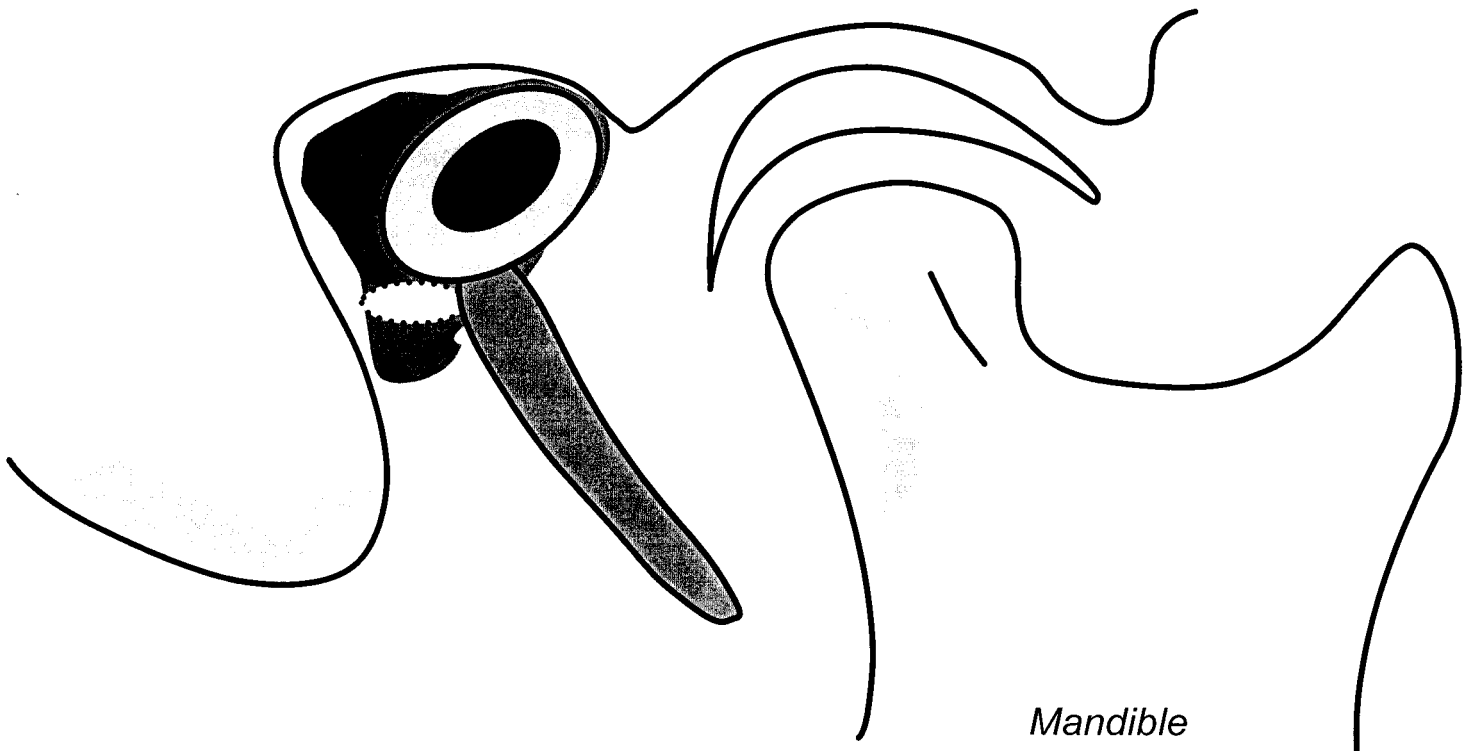



© Elsevier Ltd 2005. Standing: Gray's Anatomy 39e



© Elsevier Ltd 2005. Standing: Gray's Anatomy 39e

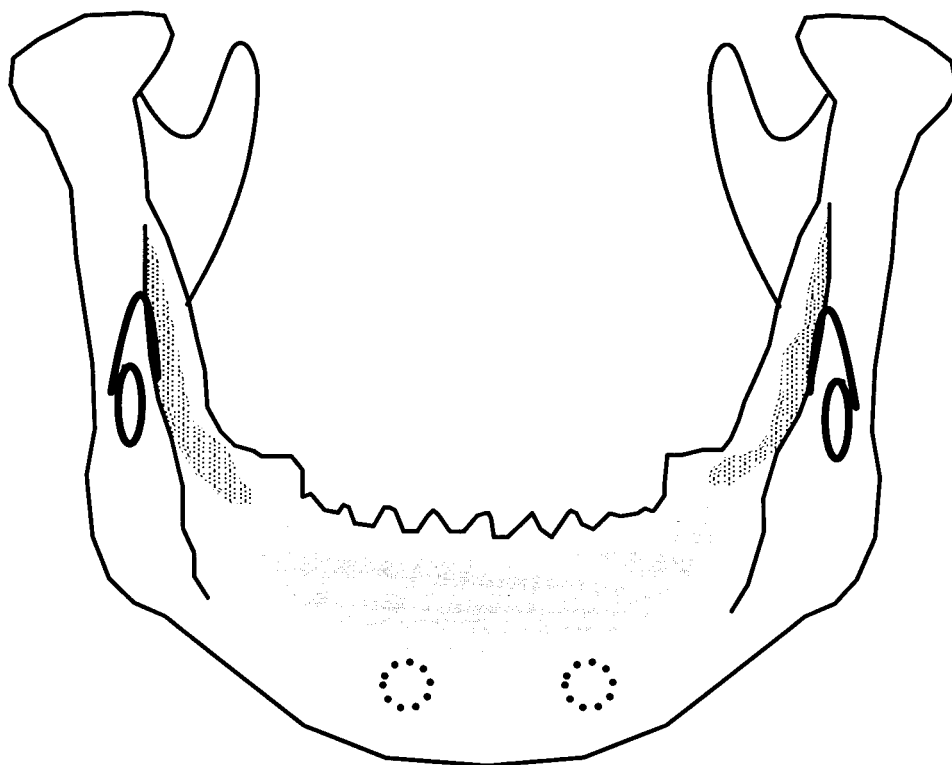
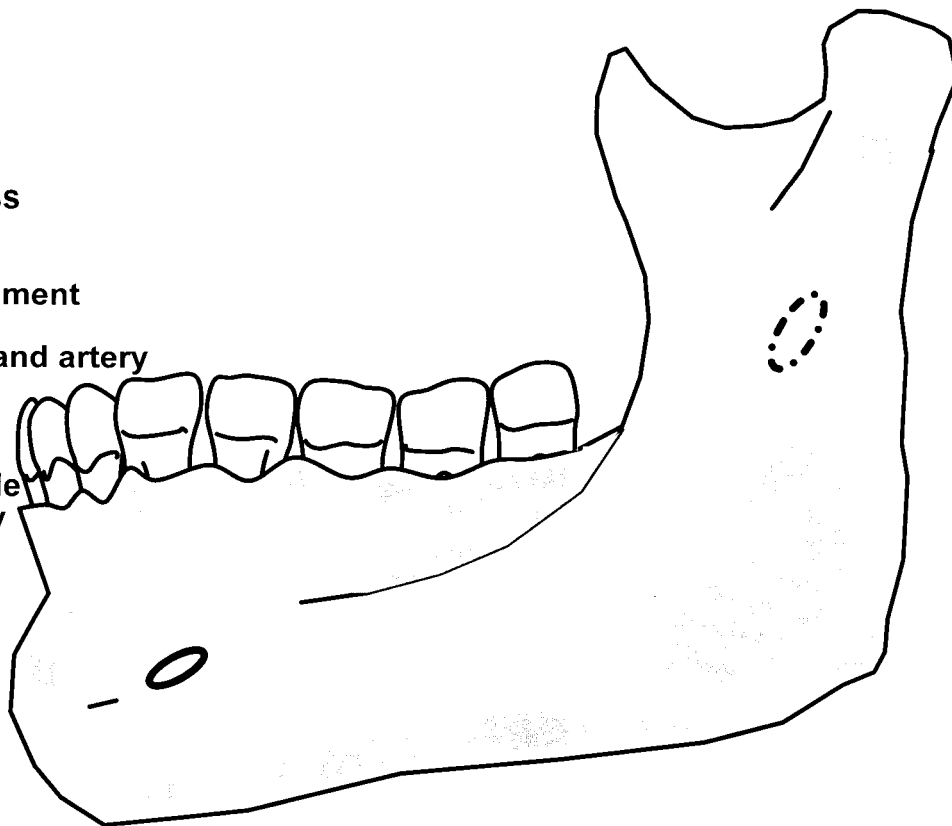
Temporomandibular Joint



- | | |
|------------------------------|---|
| 1. Mastoid process | 15. Articular Disk |
| 2. Styloid process | 16. Inferior synovial cavity |
| 3. Stylomastoid foramen | 17. Superior head of lateral pterygoid |
| 4. External acoustic meatus | 18. Inferior head of lateral pterygoid |
| 5. Postglenoid tubercle | 19. Posterior fibers of temporalis |
| 6. Mandibular fossa | 20. Anterior fibers of temporalis |
| 7. Articular tubercle | 21. Facial nerve |
| 8. Condyle | 22. Auriculotemporal nerve |
| 9. Mandibular notch | 23. Communicating branch (parasympathetics) |
| 10. Masseteric artery | 24. Posterior belly digastric |
| 11. Masseteric nerve | 25. Stylohyoid muscle |
| 12. Coronoid process | 26. Lesser occipital nerve |
| 13. Articular capsule | 27. Great auricular nerve |
| 14. Superior synovial cavity | 28. Parotid Gland |

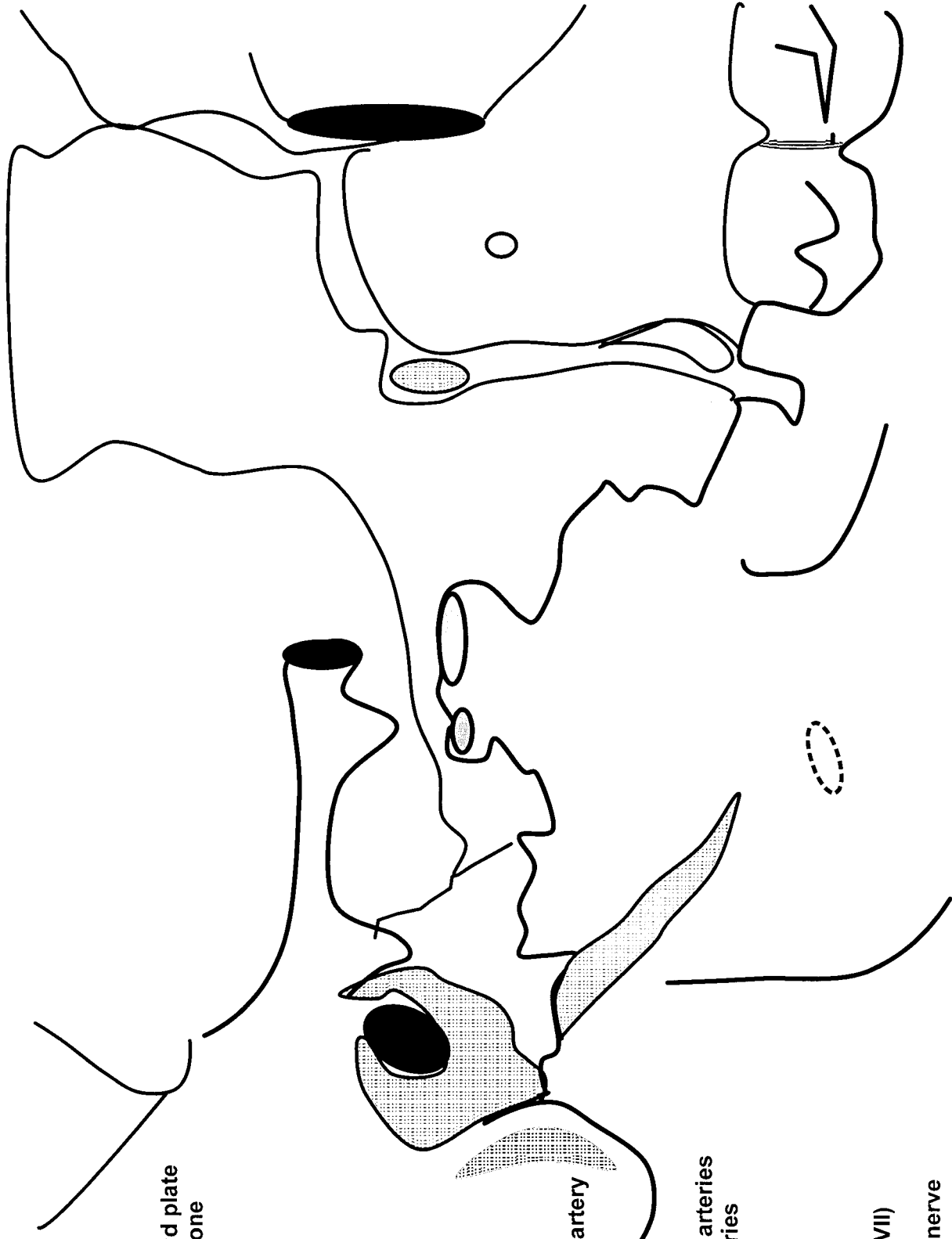
Lateral and Posterior View of Mandible

1. Condyle
2. Neck
3. Coronoid process
4. Mandibular notch
5. Ramus
6. Angle
7. Body
8. Inferior alveolar process
9. Mandibular foramen
10. Lingula
11. Sphenomandibular ligament
12. Mental foramen
13. Inferior alveolar nerve and artery
14. Inferior dental plexus
15. Temporalis muscle
16. Masseter muscle
17. Medial pterygoid muscle
18. Mental nerve and artery



Nerves of the Infratemporal Fossa

1. Zygomatic process temporal bone
2. Mastoid process
3. External auditory meatus
4. Styloid process
5. Petrotympenic fissure
6. Lateral pterygoid plate
7. Maxilla
8. Temporal process maxilla
9. Hamulus of medial pterygoid plate
10. Greater wing of sphenoid bone
11. Inferior orbital fissure
12. Pterygomaxillary fissure
13. Pterygopalatine fossa
14. Foramen spinosum
15. Foramen ovale
16. Sphenopalatine foramen
17. External carotid artery
18. Superficial temporal artery
19. Maxillary artery
20. Deep auricular artery
21. Inferior alveolar artery
22. Middle meningeal artery
23. Deep temporal arteries
24. Buccal artery
25. Posterior superior alveolar artery
26. Infraorbital artery
27. Artery of maxillary nerve
28. Artery of pterygoid canal
29. Pharyngeal artery
30. Greater and lesser palatine arteries
31. Lateral posterior nasal arteries
32. Mandibular nerve
33. Auriculotemporal nerve
34. Inferior alveolar nerve
35. Lingual nerve
36. Buccal nerve
37. Chorda tympani nerve (CN VII)
38. Maxillary nerve
39. Posterior superior alveolar nerve
40. Infraorbital nerve
41. Mandibular Foramen
42. Facial Nerve
43. Communicating branch - parasympathetics



Arteries of the Infratemporal Fossa

1. Zygomatic process temporal bone
2. Mastoid process
3. External auditory meatus
4. Styloid process
5. Petrotympenic fissure
6. Lateral pterygoid plate
7. Maxilla
8. Temporal process maxilla
9. Hamulus of medial pterygoid plate
10. Greater wing of sphenoid bone
11. Inferior orbital fissure
12. Pterygomaxillary fissure
13. Pterygopalatine fossa
14. Foramen spinosum
15. Foramen ovale
16. Sphenopalatine foramen
17. External carotid artery
18. Superficial temporal artery
19. Maxillary artery
20. Deep auricular artery
21. Inferior alveolar artery
22. Middle meningeal artery
23. Deep temporal arteries
24. Buccal artery
25. Posterior superior alveolar artery
26. Infraorbital artery
27. Artery of maxillary nerve
28. Artery of pterygoid canal
29. Pharyngeal artery
30. Greater and lesser palatine arteries
31. Lateral posterior nasal arteries
32. Mandibular nerve
33. Auriculotemporal nerve
34. Inferior alveolar nerve
35. Lingual nerve
36. Buccal nerve
37. Chorda tympani nerve (CN VII)
38. Maxillary nerve
39. Posterior superior alveolar nerve
40. Infraorbital nerve
41. Mandibular Foramen
42. Facial Nerve
43. Communicating branch - parasympathetics

