

STRUCTURAL BASIS OF MEDICAL PRACTICE

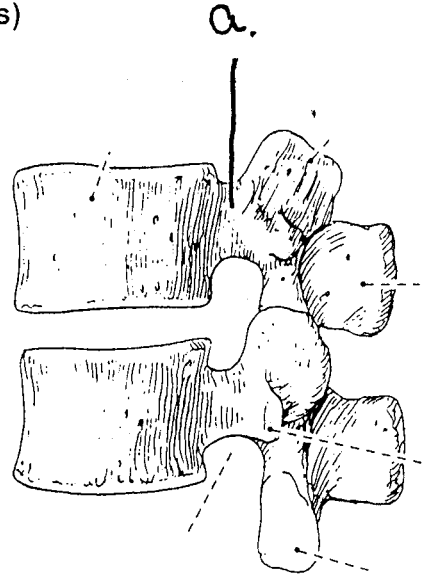
EXAMINATION I

August 31, 2006

PART I. Answer in the space provided. (5 pts)

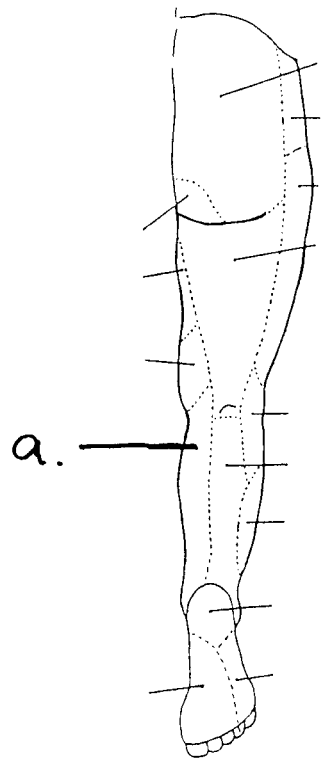
1. Identify the structure. (0.5 pt)

a. Pedicle



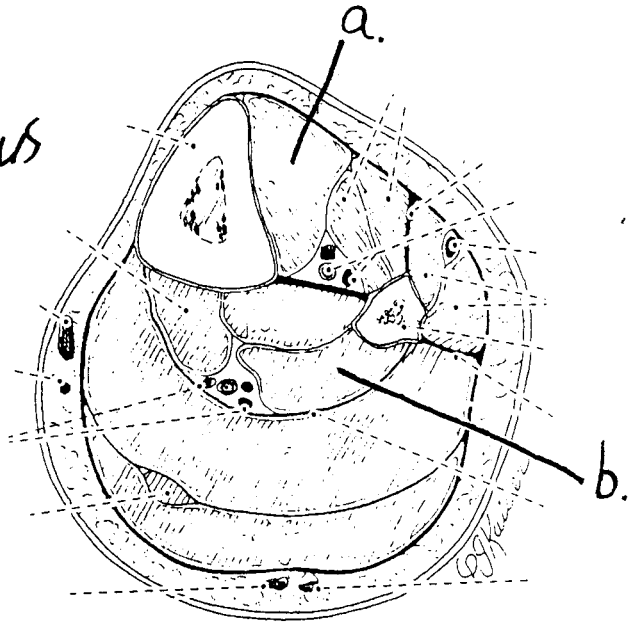
2. Identify the innervation. (0.5 pt)

a. Saphenous Nerve



3. Identify the structures. (1 pt)

a. Tibialis Anterior
b. Flexor Hallucis Longus



4. Identify the structures. (1 pt)

a. Rectus Femoris
b. Biceps Femoris

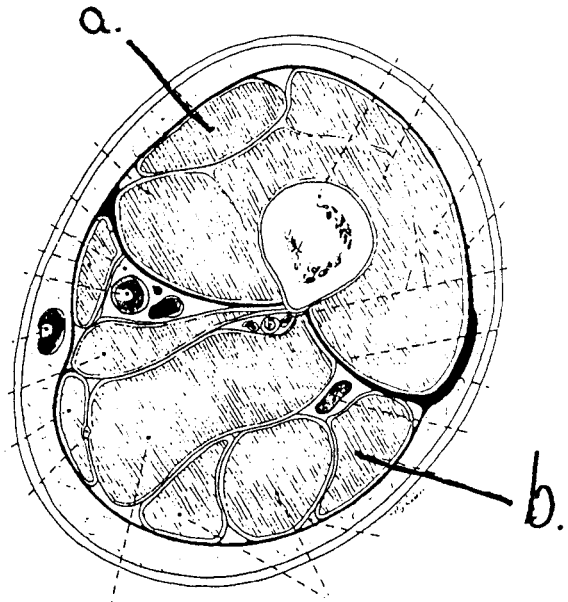


FIGURE 18-10.
A transverse section through the middle third of the thigh

5. Identify the structure. (0.5 pt)

a. Medial Tibial Genicular Artery

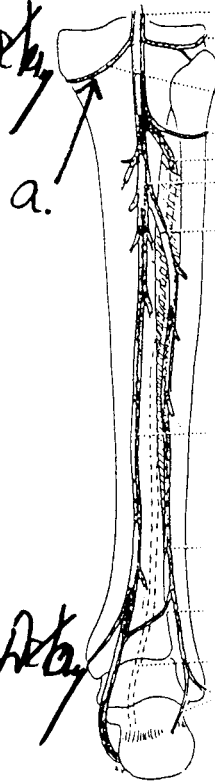


FIGURE 18-29.
Diagram of the arteries of the leg: posterior view.

6. Identify the structure. (0.5 pt)

a. Anterior Lateral Malleolar Artery

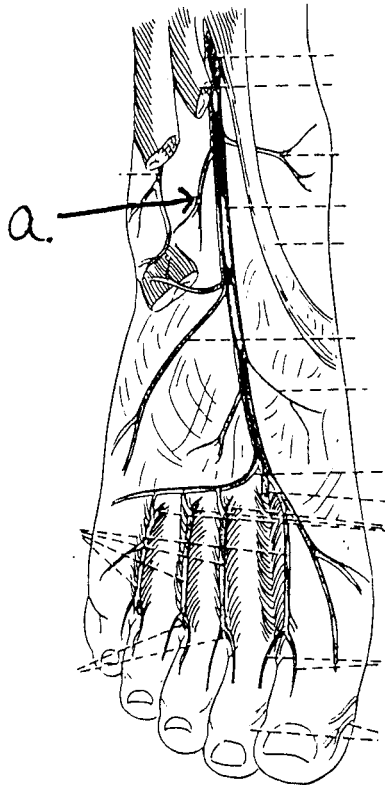
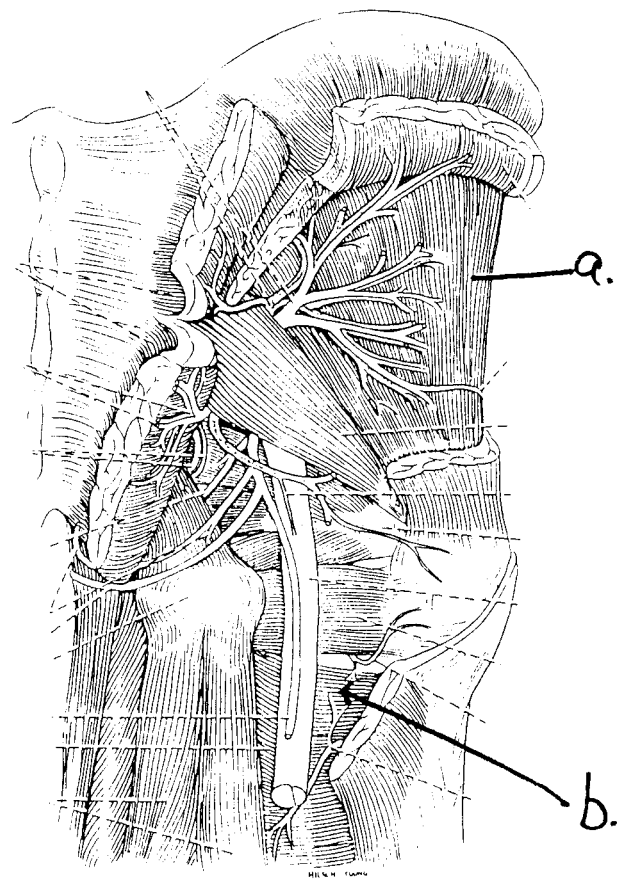


FIGURE 18-48.
the arteries on the dorsum of the foot

7 Identify the structures. (1 pt)

- a. Gluteus minimus
- b. Adductor magnus



Part II. Circle the correct answer. All, none, or some may apply. (29 pts)

1. With respect to the nervous system:

- a. There are white rami at the level of S1-4.
- b. The vagus nerve contains pre- and post-ganglionic neurons.
- c. The parietal layer of serous pericardium is innervated by the phrenic nerve.
- d. Pre-ganglionic neurons of the parasympathetic nervous system are generally quite long compared to post-ganglionic neurons.
- e. The somatic afferent fibers have cell bodies in the ventral horn.
- f. The adductor magnus is an example of a skeletal muscle innervated by the somatic nervous system.
- g. The greater splanchnic nerve lies medial to the lesser splanchnic nerve.
- h. Sympathetic innervation to the heart dilates the coronary arteries.
- i. Pre-ganglionic neurons in the vagus synapse with post-ganglionic neurons at S2-4 of the sympathetic trunk.
- j. The deep cardiac plexus contains post-ganglionic neurons of the sympathetic nervous system.

2. With respect to the gluteal region:

- a. From the posterior perspective, the obturator externus muscle lies deep to the quadratus femoris.
- b. The internal pudendal artery exits the greater sciatic foramen on the superior border of the piriformis muscle and enters the lesser sciatic foramen on the inferior border of the piriformis muscle.
- c. The sciatic nerve courses through the greater sciatic foramen.
- d. A lesion (abnormality) of the left superior gluteal nerve will cause the pelvis to tilt to the right when the right limb is raised off the ground.

3. With regard to the subinguinal region:

- a. The femoral sheath encloses the femoral nerve.
- b. The medial circumflex artery passes posteriorly between the pectineus and adductor longus muscles.

- c. The medial femoral circumflex artery contributes to the cruciate anastomosis.
- d. Femoral hernias lie inferior and lateral to the pubic tubercle.
- e. The femoral nerve lies in the muscular lacunae.
- f. The superficial circumflex artery, superficial epigastric artery, and external pudendal artery originate from the femoral artery.

4. With respect to the lungs and ventilation:

- a. The apex of the lung reaches to 3 cm superior to the medial third of the clavicle.
- b. The pulmonary ligament contains a bronchopulmonary segment.
- c. The surface projection of the horizontal fissure follows the 6th rib.
- d. A foreign body is more likely to lodge in the right bronchus.

5. In regard to the thorax and lungs:

- a. The surface projection of the inferior aspect of the parietal pleura in the midclavicular plane is at the level of the 8th rib.
- b. The cavity between the lung tissue and visceral pleura contains pleural fluid.
- c. The lungs are innervated by branches of the phrenic nerve.
- d. A pleural tap of the costodiaphragmatic recess can be performed in the 8th intercostal space in the midaxillary plane.
- e. Movement at the costovertebral and costotransverse joints of ribs 8-10 contribute to a change in movement in the anterior-posterior plane (termed the pump handle mechanism).
- f. The pericardiophrenic artery and vein lie in the endothoracic fascia.

6. In the thorax:

- a. The posterior intercostal arteries of the upper two intercostal spaces originate from the supreme intercostal artery that is derived from the costocervical branch of the subclavian artery.
- b. The 8th anterior intercostal artery is a branch of the internal thoracic artery.
- c. The anterior intercostal artery is innervated by the autonomic nervous system.
- d. There are 11 pair of intercostal spaces that contain innermost intercostal muscles.

- e. The right supreme (highest) intercostal vein drains into the right brachiocephalic vein.
- f. The anterior intercostal artery in the first intercostal space is derived from the brachiocephalic artery.

7. Contents of the posterior mediastinum include:

- a. Esophageal plexus.
- b. Esophagus.
- c. Arch of the aorta.
- d. Brachiocephalic veins.
- e. Azygous vein.
- f. Descending thoracic aorta.

8. With respect to the leg and the foot:

- a. Digits 2-5 have an extensor digitorum longus.
- b. The tendon of the flexor hallucis longus courses inferior to the sustentaculum tali of the calcaneus.
- c. The heads of the abductor hallucis contain sesamoid bones.
- d.** d. The lateral plantar artery courses deep to the extensor digitorum brevis.
- e. The 5th digit is adducted by the plantar interosseous muscle.
- f. The longitudinal arch includes the cuboid bone.
- g. The longitudinal arch is supported anteriorly by the heads of the metatarsal bones.
- h. The peroneus longus, tibialis anterior, and tibialis posterior are associated with suspension of the arch.

9. With regard to the lower extremity:

- a. The tibialis posterior is innervated by the peroneal nerve.
- b. The 2nd lumbrical is innervated by the lateral plantar nerve.

- c. The peroneus tertius is innervated by the superficial branch of the common peroneal nerve.
- d. The line of gravity lies posterior to the hip joint and anterior to the front of the knee and the ankle.
- e. A boundary of the popliteal fossa is the popliteus muscle.
- f. The quadratus femoris originates from the ischial tuberosity.
- g. The posterior femoral cutaneous nerve lies inferior to the piriformis muscle.
- h. Hamstring muscles extend the thigh and flex the leg.