

STRUCTURAL BASIS OF MEDICAL PRACTICE

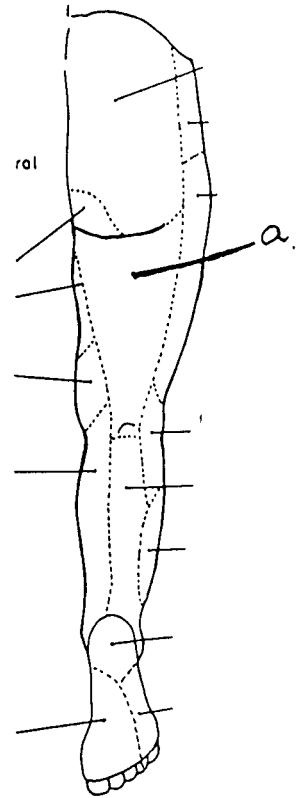
EXAMINATION I

September 2, 2004

PART I. Answer in the space provided. (7 pts)

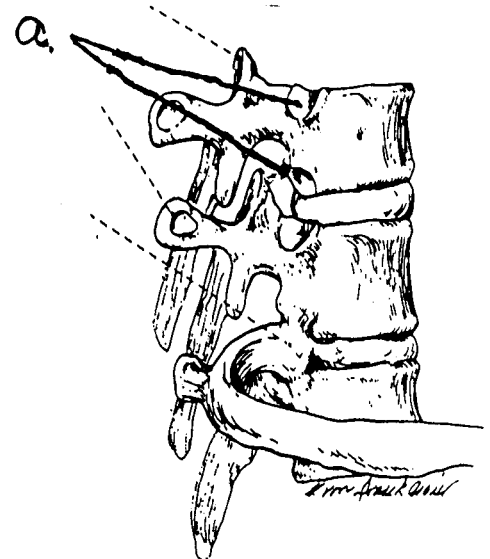
1. Identify the innervation. (0.5 pt)

a. Posterior femoral cutaneous nerve



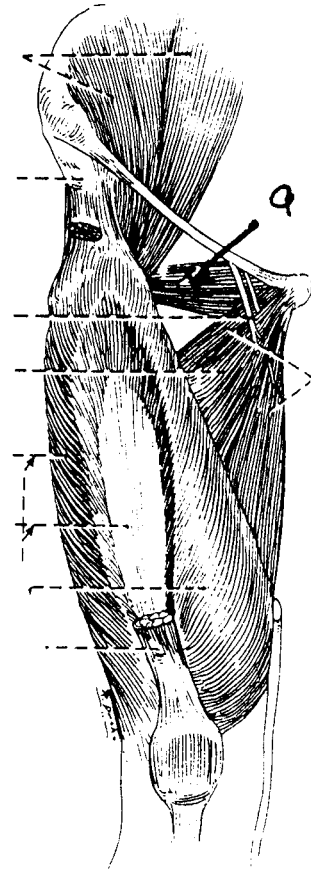
2. Identify the structures. (0.5 pt)

a. Costal facet



3. Identify the structure. (0.5 pt)

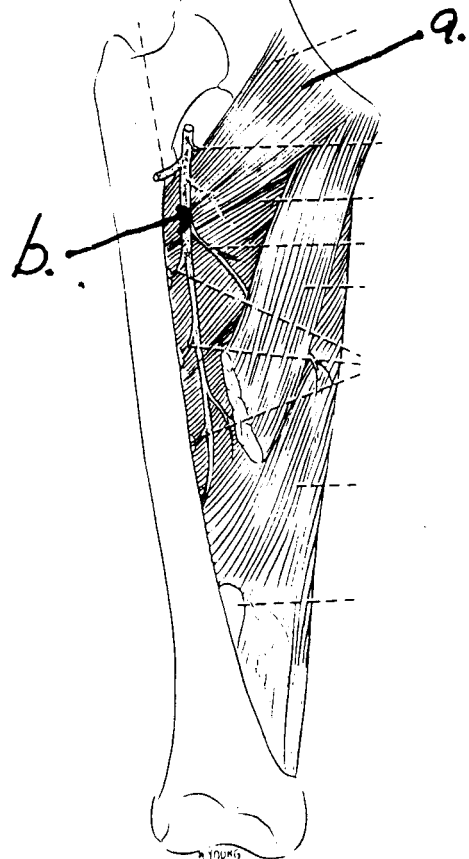
a. Obturator externus



4. Identify the structure. (1 pt)

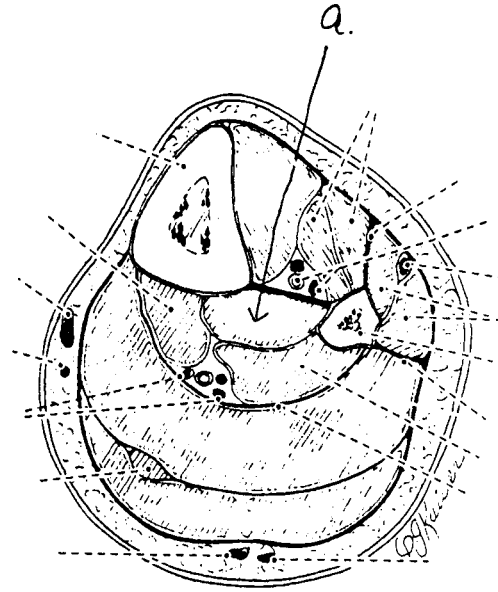
a. Pectineus

b. Deep femoral vessel (artery or vein)



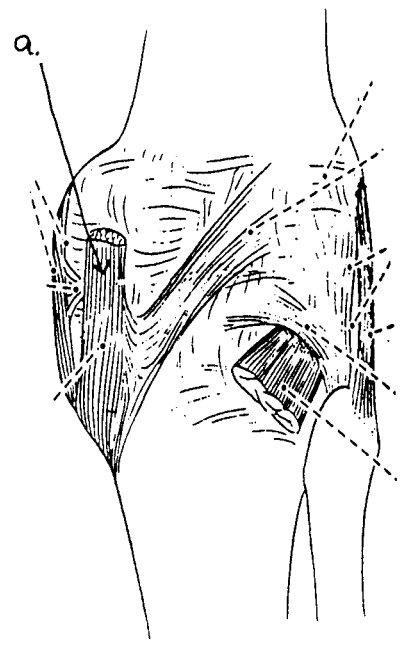
5. Identify the structure. (0.5 pt)

a. Tibialis posterior



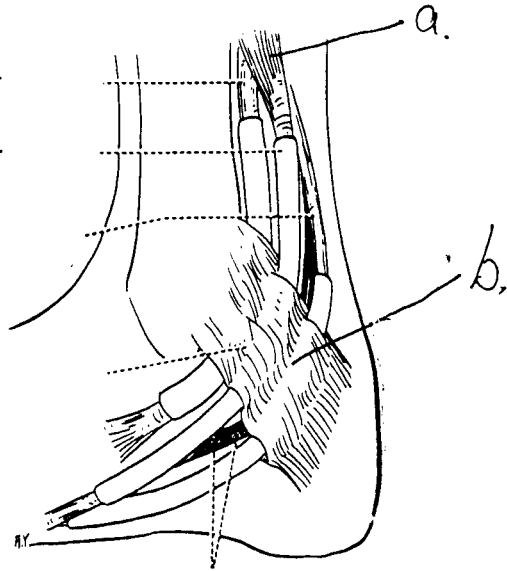
6. Identify the structure. (0.5 pt)

a. Semimembranosus



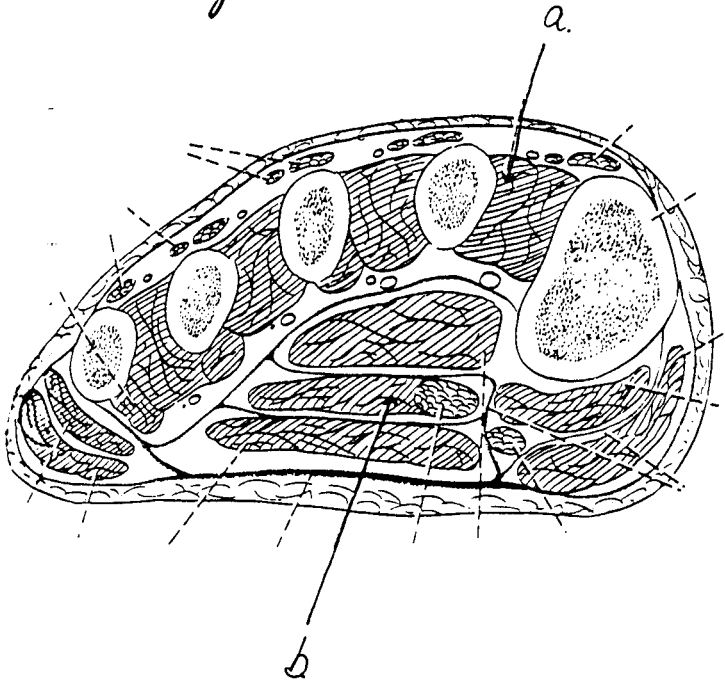
7. Identify the structure. (1 pt)

- a. Flexor digitorum longus
- b. Flexor retinaculum



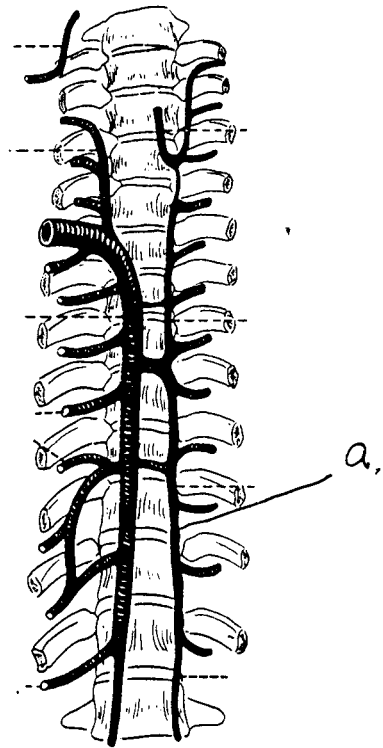
8. Identify the structure. (1 pt)

- a. First dorsal interosseus
- b. Quadratus plantae



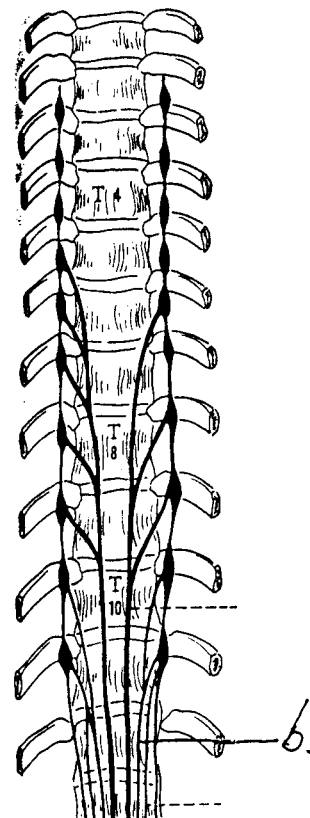
9. Identify the structure. (0.5 pt)

a. Homiozygous vein



10. Identify the structure. (0.5 pt)

a. Lesser splanchnic nerve



11. Identify the structure. (0.5 pt)

a. Anterior tibial recurrent artery

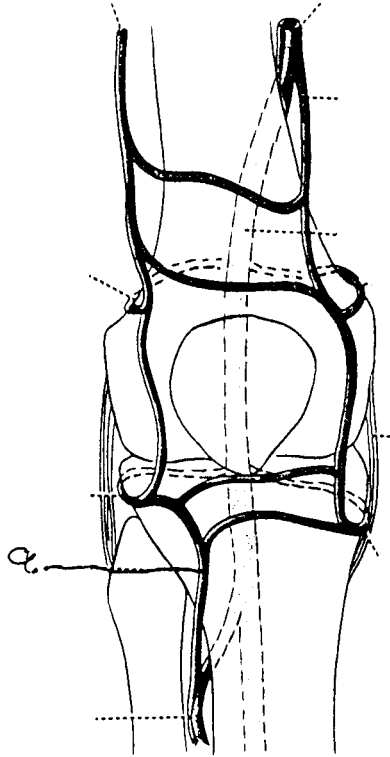


Diagram of the arteries that form an anastomosis the knee joint and supply it; anterior view.

**Part II. Circle the correct answer. All, none, or some may apply. (22 pts)**

1. With respect to the nervous system:

- a. There is a gray ramus communicans at the level of T2.
- b. The somatic efferents of the femoral nerve consist of pre- and post-ganglionic neurons.
- c. The parietal layer of serous pericardium is innervated by the phrenic nerve.
- d. Parasympathetic innervation to the heart dilates the coronary arteries.
- e. The deep cardiac plexus is located on the anterior surface of the tracheal bifurcation.
- f. The myocardium is innervated by the somatic nervous system.
- g. Post-ganglionic neurons of the parasympathetic nervous system are generally quite long compared to pre-ganglionic neurons.
- h. Preganglionic fibers of the vagus nerve do not synapse in the sympathetic trunk.

2. With regard to the subinguinal/thigh region:

- a. The femoral sheath encloses the femoral nerve.
- b. The femoral canal is cone-shaped, with its base, the femoral ring, facing into the abdomen.
- c. The superior gluteal artery contributes to the cruciate anastomosis.
- d. The descending genicular artery can be found in the adductor canal.
- e. The medial femoral circumflex artery arises from the medial aspect of the profunda (deep) femoral artery and turns posteriorly between the pectineus and adductor longus muscles.
- f. One of the heads of the rectus femoris, as well as the inguinal ligament, arise from the anterior inferior iliac spine.

3. With respect to the lungs and ventilation:

- a. The right pulmonary artery is longer than the left pulmonary artery.
- b. The cardiac notch is an area that can be utilized to introduce a needle into the pericardial sac without penetrating the pleural cavity.

c. A bronchopulmonary segment consists of a 2nd order bronchus, lung tissue, and the pulmonary artery.

(d) The inferior margin of the parietal pleura is at the level of T10 in the midaxillary line.

(e) The left principal bronchus is smaller in diameter, and approximately twice as long, as the right principal bronchus.

(f) The right bronchial vein empties into the azygous vein.

4. In regard to the thigh/popliteal fossa:

(a) The popliteal artery commences at the adductor hiatus as the continuation of the femoral artery.

(b) The medial sural cutaneous nerve is a branch of the tibial nerve.

c. The adductor magnus forms a boundary of the femoral triangle.

d. The profunda (deep) femoris vein enters the popliteal fossa.

(e) A characteristic of a hamstring muscle is innervation by the tibial portion of the sciatic nerve.

f. The medial inferior genicular artery passes superior to the medial head of the gastrocnemius muscle.

5. In the thorax:

(a) The esophagus is narrowed where it crosses the left bronchus.

(b) The right vagus nerve travels posterior to the root of the right lung.

(c) The arch of the aorta reaches the level of the fourth thoracic vertebra.

(d) The esophageal plexus is formed by the vagal nerves.

(e) In the posterior mediastinum, the thoracic duct lies deep to the esophagus.

(f) The azygous vein ascends in the posterior mediastinum to the level of the fourth thoracic vertebra, when it terminates into the superior vena cava.



6. In the foot:

- a. The oblique head of the adductor hallucis is innervated by the lateral plantar nerve.
- b. The arcuate artery runs deep to the tendons of the flexor digitorum brevis and longus.
- c. The medial and lateral calcaneal arteries arise from the dorsalis pedis artery.
- d. The 1st lumbrical muscle is innervated by the medial plantar nerve.
- e. The flexor digitorum brevis and flexor digitorum longus form, in part, the extensor expansion.
- f. The lateral plantar artery is a branch of the anterior tibial artery.

7. With respect to the lower extremity:

- a. Gravity passes anterior to the hip and posterior to the knee and the ankle.
- b. The iliofemoral ligament arises from the anterior inferior iliac spine.
- c. The popliteus muscle can medially rotate the tibia when the leg is off the ground.
- d. The tibionavicular ligament is part of the deltoid ligament.
- e. The subtalar joint is related to the talus and calcaneus.
- f. The tendon of the flexor hallucis longus lies inferior to the sustentaculum tali.

## Short Answer Key 090204

### 1. Saphenous Opening

Deficit in Fascia Lata

Opening in which venous drainage of lower extremity empties into the Femoral vein

Deficit filled with Cribiform fascia

Superior boundary is the superior cornu, inferior boundary is the inferior cornu and lateral boundary is the falciform margin

Veins which empty into the femoral vein include the great saphenous vein, superficial external pudendal vein, inferior epigastric vein and the superficial circumflex iliac vein

### 2. Lymphatic Drainage of the Lung

Pulmonary nodes to bronchopulmonary nodes to tracheobronchial nodes with paratracheal and parasternal nodes, to bronchomediastinal nodes. Lymph now is returned by two routes depending upon right and left sides. Right side by way of right lymphatic duct and left side by way of the thoracic duct.

### 3. Medial Meniscus

C-shaped, semicircular fibrocartilaginous pad located between the medial condyle and tibial plateau. Attached to the tibial collateral and anterior cruciate ligament. Located within the joint. "Unhappy triad"

### 4. Adductor Magnus

Origin: Inferior pubic ramus and ramus of ischium/ischial tuberosity

Insertion: Posterior shaft of femur at the linea aspera and the adductor tubercle

Action: Adduct thigh and assists with lateral rotation and extends thigh at hip

Innervation: Obturator nerve and tibial portion of sciatic nerve

Blood Supply: Profunda femoris artery by way of the perforating artery

Adductor hiatus

### 5. Ligamentum Capitis

Attaches to fovea capitis and to transverse acetabular ligament and acetabular notch. Located within joint. Limits adduction. Contains blood supply from posterior obturator artery. Damage to arterial supply can lead to avascular necrosis.

### 6. Insertion of Flexor muscles into the 3<sup>rd</sup> Digit

Flexor digitorum longus inserts into the distal phalanx. Flexor digitorum brevis inserts into the middle phalanx after splitting to allow the long tendon of flexor digitorum longus to reach the distal phalanx. Lumbricals flex at the MP joint and insert onto the extensor expansion