

STRUCTURAL BASIS OF MEDICAL PRACTICE

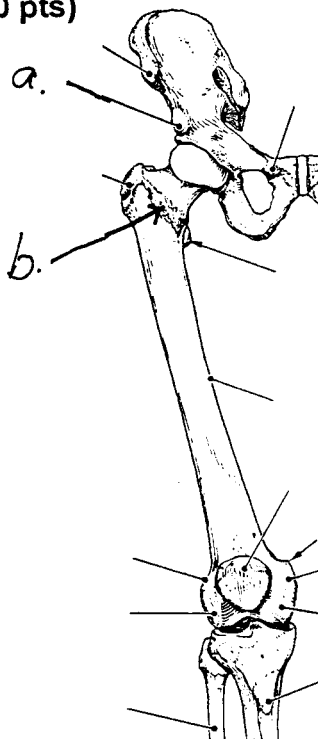
EXAMINATION I

August 30, 2002

PART I. Answer in the space provided. (10 pts)

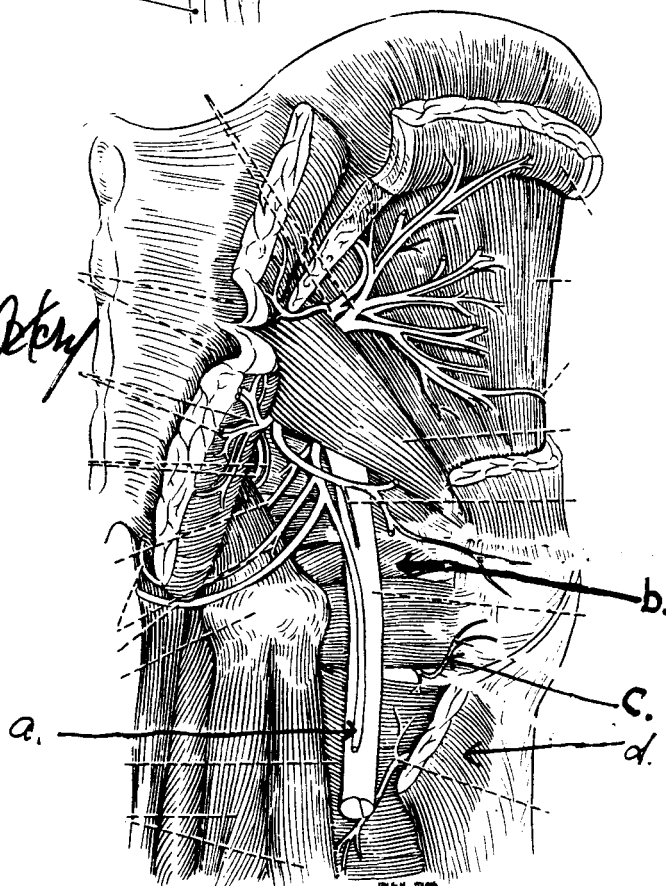
1. Identify the structures. (1 pt)

- a. Ant. intercostal spine
- b. Intercostal Line



2. Identify the structures. (2 pts)

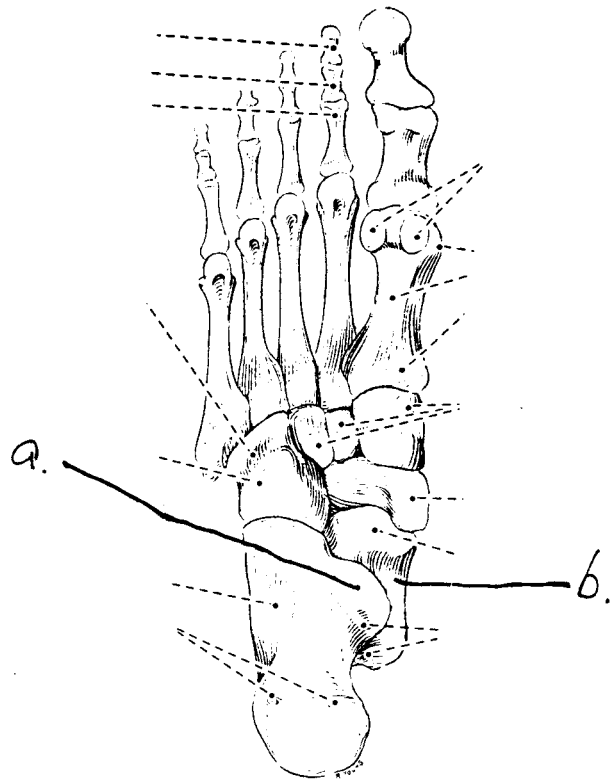
- a. Post. Femoral Cutaneous Nerve
- b. Inferior Gemelli
- c. Medial Femoral Circumflex Artery
- d. Gluteus Maximus



3. Identify the structures. (1 pt)

a. Sustentaculum tali

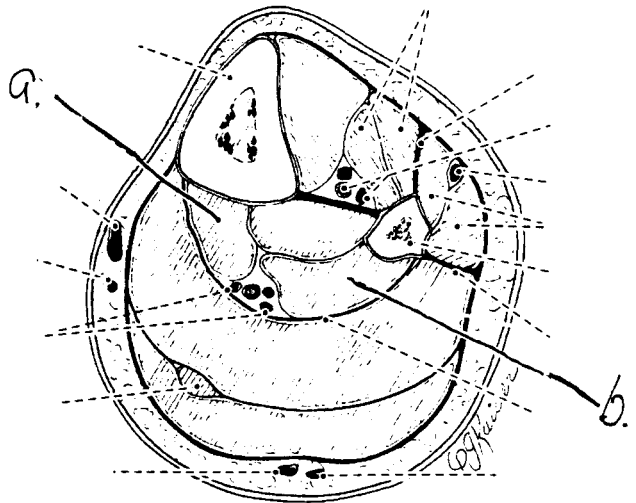
b. Talus



4. Identify the structures. (1 pt)

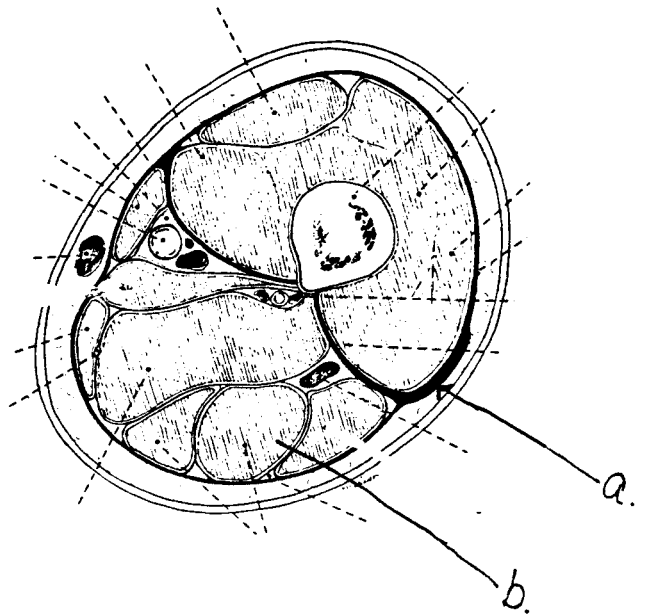
a. Fibula digitorum longae

b. Fibula hallucis longae



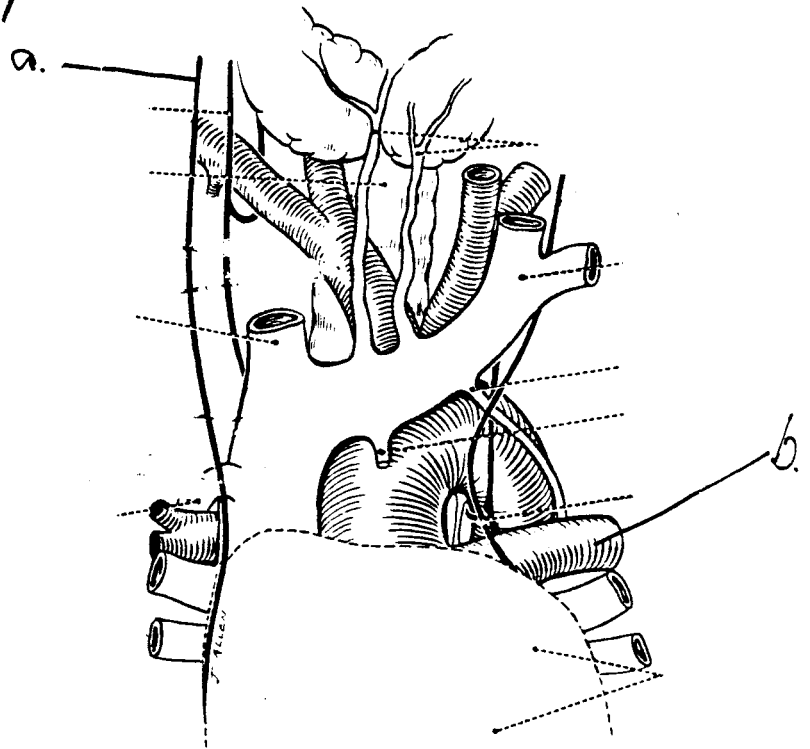
5. Identify the structures. (1 pt)

- a. Ilio Tibial Band
- b. Semitendinosus



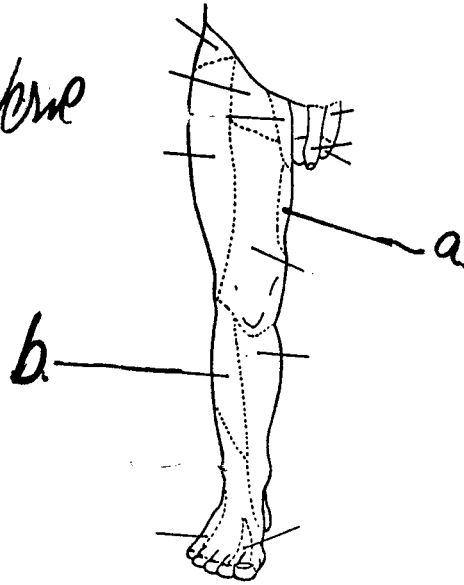
6. Identify the structures. (1 pt)

- a. Phrenic Nerve
- b. Left Pulmonary Artery



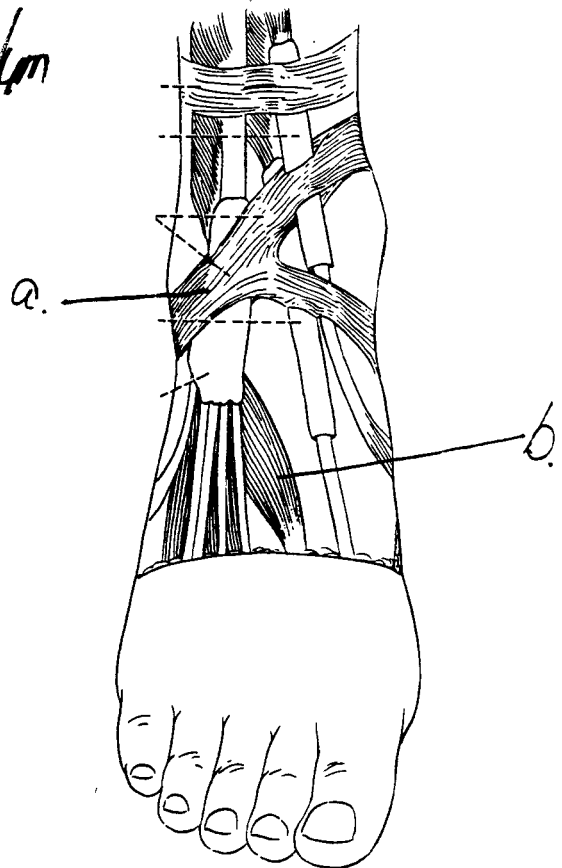
7. Identify the structures. (1 pt)

- a. Obturator Nerve
- b. Lateral Sural Cutaneous Nerve



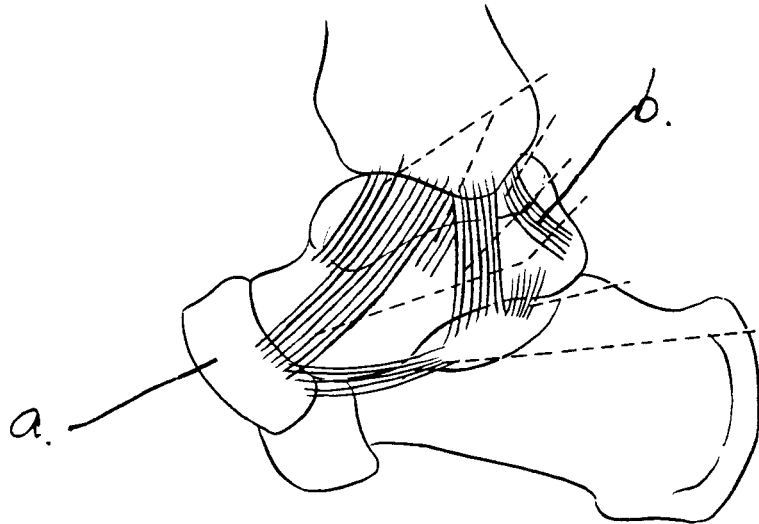
8. Identify the structures. (1 pt)

- a. Inferior Extensor Retinaculum
- b. Extensor Hallucis Brevis



9. Identify the structures, (1 pt)

- a. Mucous fold
- b. Posterior Tibiofemoral Ligament



Part II. Circle the correct answer. All, none, or some may apply. (41 pts)

1. With regard to the vasculature:

- a. The anterior medial tarsal artery originates from the dorsalis pedis and continues with the posterior medial tarsal artery which is a branch of the posterior tibial artery.
- b. The anterior tibial recurrent artery arises from the anterior tibial artery.
- c. The lateral calcaneal artery arises from the peroneal artery.
- d. The descending genicular artery arises from the femoral artery in the adductor canal.
- e. The medial femoral circumflex artery passes posteriorly between the pectineus and adductor longus muscles.
- f. Blood drains from deep to superficial veins in the thigh.

2. With respect to the nervous system:

- a. There are gray rami at levels T1-4.
- b. The somatic efferents of the femoral nerve consist of pre- and post-ganglionic neurons.
- c. The parietal layer of serous pericardium is innervated by the phrenic nerve.
- d. Pre-ganglionic neurons of the parasympathetic nervous system are generally quite long compared to post-ganglionic neurons.
- e. The somatic afferent fibers have cell bodies in the dorsal root ganglion.
- f. The diaphragm is an example of a skeletal muscle innervated by the autonomic nervous system.

3. With respect to the gluteal region:

- a. Intragluteal injections are placed in the superior lateral quadrant.
- b. The superior and inferior gemellus, quadratus femoris, obturator externus, obturator internus, and gluteus medius and minimus are lateral rotators of the thigh.
- c. The tensor fascia lata is innervated by the superior gluteal nerve.

d. The superior gluteal artery exits the lesser sciatic foramen on the superior border of the piriformis muscle.

e. The tendon of the obturator internus courses through the lesser sciatic foramen.

4. With regard to the mediastinum:

a. The vagus nerve courses through the superior mediastinum.

b. The superficial cardiac plexus is located in the superior mediastinum.

c. The sternopericardial ligament is located in the middle mediastinum.

d. The hemiazygous vein is located in the middle mediastinum.

e. The thoracic duct is located in the posterior mediastinum.

5. With respect to the heart:

a. The base of the heart is positioned anterior, inferior, and to the left.

b. The venous mesocardium is a reflection of pericardium that is associated with the coronary sinus.

c. The circumflex artery is a branch of the marginal artery.

d. The small cardiac vein drains blood into the coronary sinus.

e. The SA node is located in the epicardium at the atrioventricular valve.

6. With regard to the heart:

a. Medial (septal) papillary muscles are found in the right ventricle.

b. The atrioventricular valves have nodules and lunules.

c. The ligamentum arteriosum extends from the pulmonary trunk to the aorta.

d. The papillary muscles contract and stabilize the atrioventricular cusps when blood passes from the atria to the ventricle.

e. Trabeculae carneae are in the right ventricle but not the left ventricle.

7. In the lower extremity:

a. The popliteus muscle flexes the leg and rotates the leg medially.

b. The lateral inferior genicular artery passes across the popliteus muscle.

c. The popliteus muscle is innervated by the deep peroneal nerve.

d. The gastrocnemius arises from posterior surface of the tibia.

e. The peroneus tertius and peroneus brevis insert on to the 5th metatarsal bone.

8. With regard to the knee:

a. The anterior cruciate ligament prevents the forward (anterior) displacement of the tibia.

b. The menisci are lined by synovial membrane.

c. The medial meniscus is attached to the tibial collateral ligament.

d. The popliteus muscle is intracapsular but extrasynovial in the knee joint.

e. The line of gravity falls in front of the knee when standing.

9. With regard to the anterior thigh:

a. The falciform margin is formed by tela subcutanea and forms the lateral portion of the saphenous hiatus.

b. The femoral canal is located medial to the femoral vein.

c. Femoral hernias occur inferior and lateral to the pubic tubercle.

d. The femoral vein is in the vascular lacuna.

e. Femoral hernias protrude into the adductor canal.

10. With respect to the thigh:

a. The saphenous nerve is a branch of the obturator nerve located in the adductor canal.

b. The femoral triangle is formed by the inguinal ligament, adductor magnus, and sartorius muscles.

c. The femoral canal is in the femoral triangle.

d. The superficial circumflex iliac artery originates from the femoral artery in the femoral triangle.

e. The hamstring muscles arise from the ischial tuberosity, cross the hip and knee joints, and are innervated by the common peroneal nerve.

11. With respect to the lower extremity:

- a. A patient with footdrop of the right limb has damage to the left common peroneal nerve.
- b. A patient with footdrop of the right limb compensates for maintaining balance by shifting weight towards the left limb.
- c. Footdrop and footslap are related to damage of the muscles for plantar flexion.
- d. Footslap is a dysfunction of the lower extremity related to pelvic sag (Trendelenberg's gait).
- e. Cutaneous innervation from the deep peroneal nerve can be tested on the dorsal surface of the foot between the great toe and the 2nd digit.

12. Relationships:

- a. The carina is at the level of T4.
- b. The inferior extent of the costal margin is at S4.
- c. The superior extent of the arch of the aorta is at the level of T1.
- d. The superior extent of the iliac crest is located at the level of L4.
- e. The thoracic projection of the tricuspid valve of the heart is at the junction of the sternum and the 1st rib.
- f. In quiet breathing, the apex of the heart is located at the left 5th intercostal space just medial to the midclavicular line.
- g. The sternal angle (angle of Louis) is at the level of T4.
- h. The piriformis muscle can be palpated from the dorsal surface.
- i. The epicondyles but not the adductor tubercle can be palpated.

13. In the foot:

- a. The medial plantar nerve innervates the abductor hallucis.
- b. The lumbricals flex the metatarsal-phalange joint and extend the interphalangeal joints.
- c. A lesion of the lateral plantar nerve could cause paralysis of the dorsal interosseous muscles.

- d. The medial plantar nerve innervates the flexor digitorum brevis.
- e. The plantar arterial arch of the lateral plantar artery passes dorsal to the oblique head of the adductor hallucis.
- f. The dorsal digital expansions of digits 3 and 4 are formed by aponeurotic expansions of several muscles, including the interossei, extensor digitorum longus and brevis, and lumbricals.

14. In the thorax:

- a. The anterior intercostal nerve arises from the internal thoracic nerve.
- b. The transversus thoracis muscles lie deep (posterior) to the internal thoracic artery.
- c. The external intercostal membrane has muscle fibers coursing in the cephalic direction.
- d. Endothoracic fascia is located between the external and internal intercostal muscles.
- e. The 4th intercostal nerve is located between the external and internal intercostal muscles.
- f. There are 11 pair of internal intercostal muscles.

15. With respect to the thorax:

- a. Foreign bodies are prone to lodge in the esophagus where it is narrowed by the arch of the aorta.
- b. Foreign bodies are prone to lodge in the right bronchus.
- c. The esophagus is narrowed where it crosses the left bronchus.
- d. A bronchopulmonary segment includes lung tissue, a 3rd order bronchus, and branch of the pulmonary artery.

EXAM NUMBER _____

Part III. Answer in the space provided (including the back of the page for each question). (49 pts)

1. The incidence of breast cancer in the U.S. is approximately 200,000 each year, and over 40,000 fatalities occur annually. In fact, 1 in every 13 women will be afflicted with breast cancer during their lives. Tumors of the breast metastasize (spread) through the lymphatic channels. **Describe the lymphatic drainage of the breast.** (6 pts)

EXAM NUMBER _____

2. As a 1st year resident serving a rotation in the emergency room, a 55-yr old female patient presents with complaints of pain in the "back of the knee" and difficulty in walking. Your diagnosis reveals a pulsating popliteal mass with a palpable "thrill" (vibration) and audible "bruit" (a harsh sound). At your weekly conference, you are asked to: **Discuss the anatomy of the popliteal fossa, and include an account of the boundaries, vascular supply, innervation, ligaments, bones, contents, muscles, and relationships.** (12 pts)

EXAM NUMBER _____

3. A 63-yr old man with extensive osteoarthritis of the right hip joint is about to undergo surgery for total hip joint replacement with a prosthesis. You are aware that osteoarthritis is the most common disease of the hip joint in adult, and causes pain, stiffness, and deformity. As the attending physician, you want to present a review of the hip joint. **Discuss the anatomy of the hip joint. Include an account of the innervation, vascular supply, ligaments, bones and articulations, movements and limitations of movements, and stability.** (12 pts)

EXAM NUMBER _____

4. A 26-yr old male presents with a stab wound to the thorax; the wound penetrates into the thoracic cavity and extensive bleeding is noted. At daily rounds, you are asked to: **Discuss the collateral circulation of the arterial supply and venous drainage of the thoracic wall, and relate this to the structure (muscles, bones, fascia) comprising the thoracic cage.** (10 pts)

EXAM NUMBER _____

5. Postoperative pulmonary atelectasis (failure of the lungs to expand) is a common complication after surgery, and involves a lobe or an entire lung that may collapse. At Grand Rounds, you are asked to: **Discuss the mechanics of breathing, focusing on explaining the basic movements of the thoracic cage and expansion of the lung in respiration.** (9 pts)