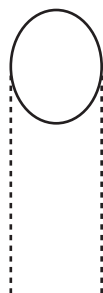
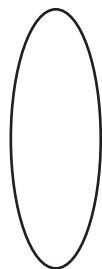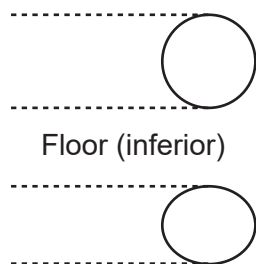


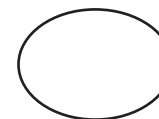
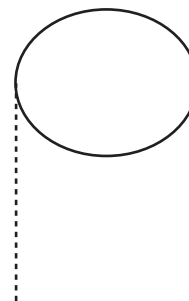


# Schematic of Pterygopalatine Fossa and Ganglion

1. Foramen rotundum
2. Pterygoid canal
3. Pharyngeal canal
4. Lesser palatine canal
5. Greater palatine canal
6. Sphenopalatine foramen
7. Inferior orbital fissure
8. Pterygomaxillary fissure
9. Pterygopalatine ganglion
10. Maxillary nerve
11. Pharyngeal nerve
12. Lesser palatine nerve
13. Greater palatine nerve
14. Lateral posterior nasal nerves
15. Nasopalatine nerve
16. Infraorbital nerve
17. Posterior superior alveolar nerve
18. Greater superficial petrosal nerve (GSPN)
19. Deep petrosal nerve
20. Sphenopalatine n.

**Medial**



**Anterior**



**Lateral**

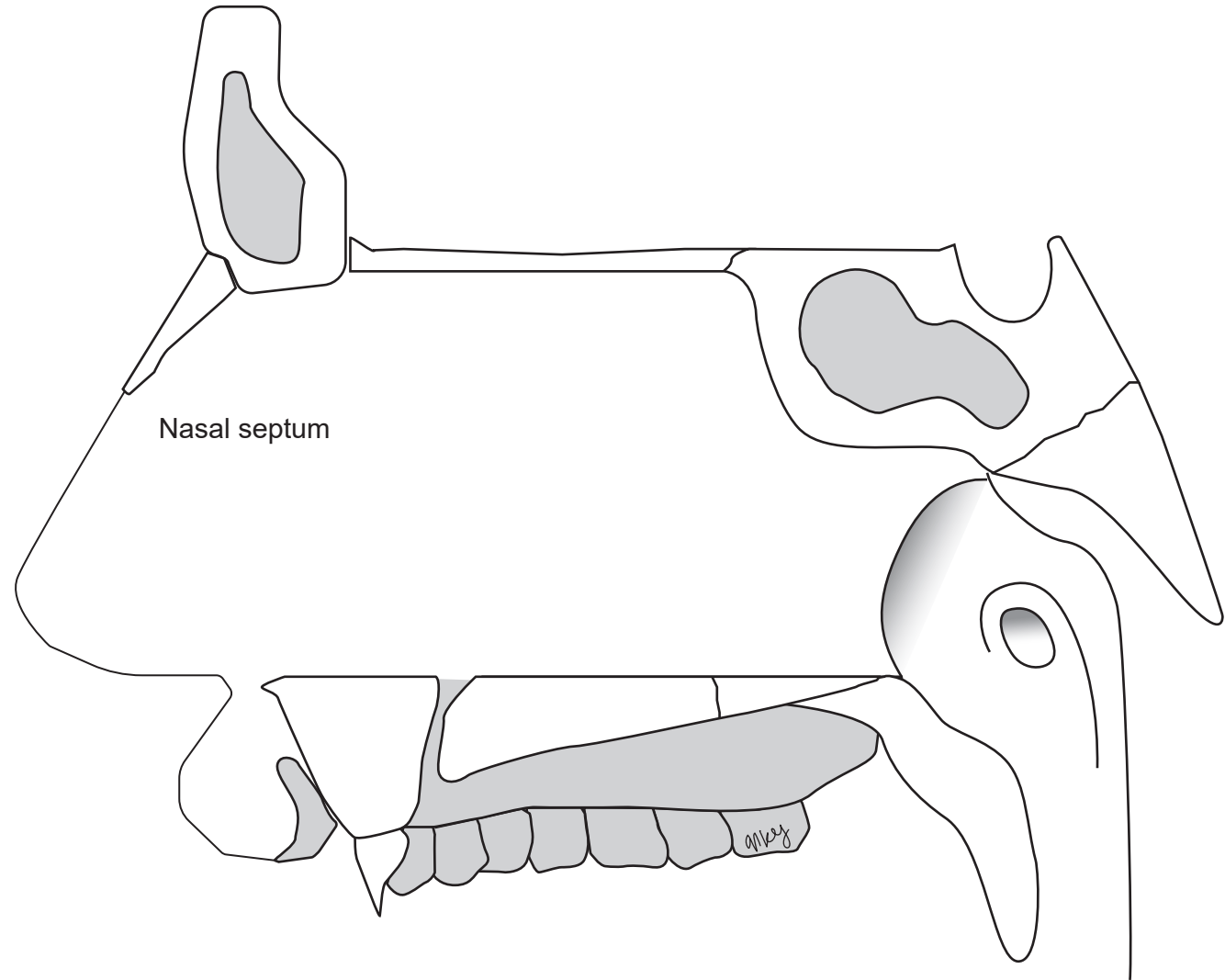


**Posterior**

# Trigeminal Nerve Branches: Nasal septum

Illustrations by Natalie Yoshioka

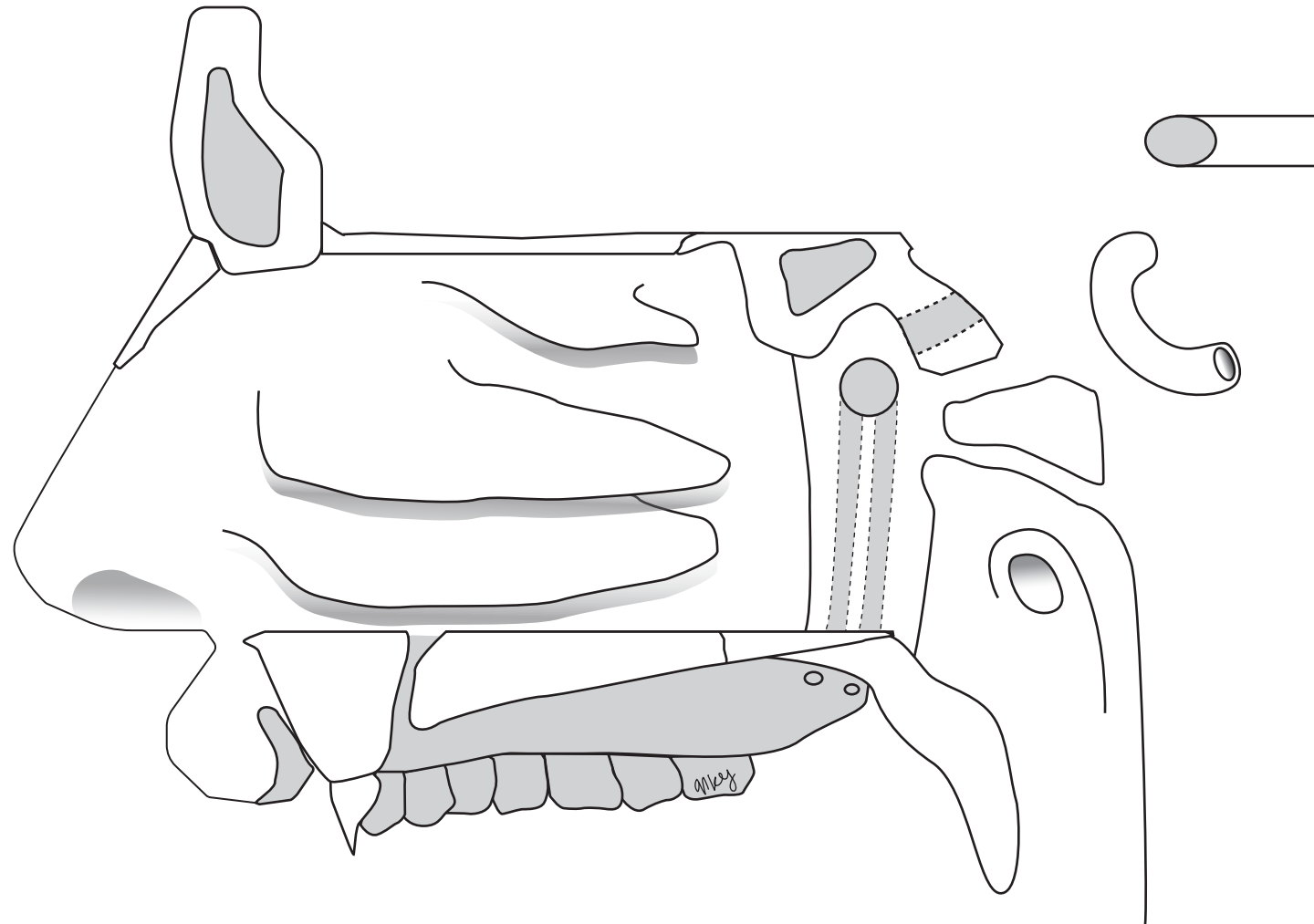
1. Frontal sinus
2. Sphenoid sinus
3. Ostium of auditory tube
4. Incisive canal
5. Nasopalatine nerve
6. Optic canal



# Pterygopalatine Ganglion and Lateral Nasal Wall

Illustrations by Natalie Yoshioka

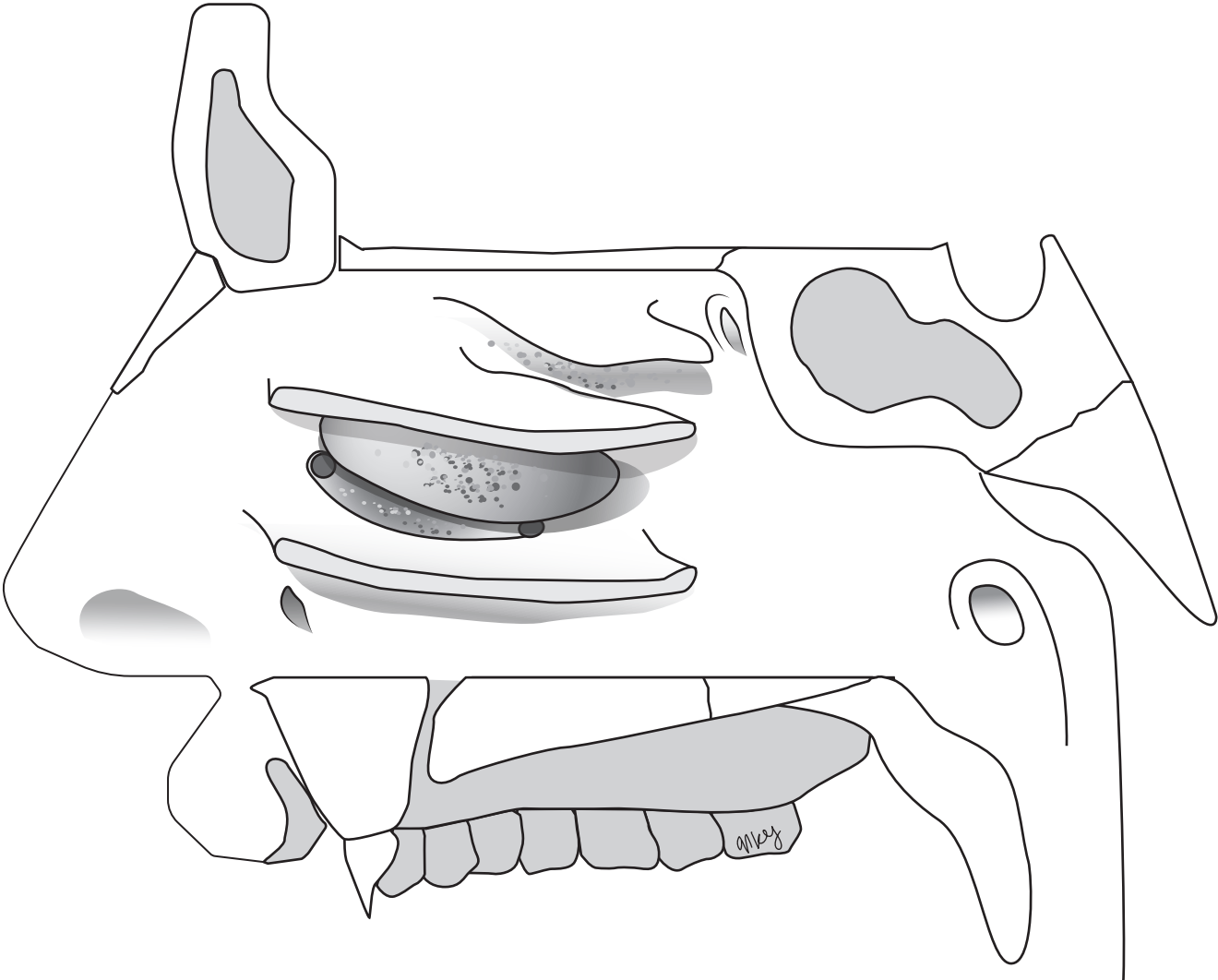
1. Frontal sinus
2. Sphenoid sinus
3. Cribriform plate of the ethmoid bone
4. Hard palate
5. Soft palate
6. Superior nasal concha
7. Middle nasal concha
8. Inferior nasal concha
9. Foramen rotundum
10. Pterygoid canal
11. Pharyngeal canal
12. Lesser palatine canal
13. Greater palatine canal
14. Sphenopalatine foramen
15. Pterygomaxillary fissure
16. Maxillary nerve
17. Posterior superior alveolar nerve
18. Infraorbital nerve
19. Lateral posterior superior nasal nerve
20. Lateral posterior middle nasal nerve
21. Lateral posterior inferior nasal nerve
22. Greater palatine nerve
23. Lesser palatine nerve
24. Pharyngeal nerve
25. Greater superficial petrosal nerve (GSPN)
26. Hiatus of the canal GSPN
27. Pterygopalatine ganglion
28. Internal carotid artery
29. Internal carotid plexus
30. Deep petrosal nerve (DPN)
31. Nerve of pterygoid canal (Vidian)
32. Anterior ethmoidal nerve and artery
33. Internal nasal nerve
34. External nasal nerve
35. Ostium of auditory tube



# Osteomeatal Complex

Illustrations by Natalie Yoshioka

- 1. Superior nasal concha
- 2. Middle nasal concha
- 3. Inferior nasal concha
- 4. Superior nasal meatus
- 5. Middle nasal meatus
- 6. Inferior nasal meatus
- 7. Opening to the sphenoid sinus
- 8. Posterior ethmoidal air cells
- 9. Ethmoid bullae
- 10. Semilunar hiatus
- 11. Middle ethmoidal air cells
- 12. Frontonasal duct
- 13. Anterior ethmoidal air cells
- 14. Opening to the maxillary sinus
- 15. Nasolacrimal duct



# Trigeminal Nerve Branches: Orbit

Illustrations by Natalie Yoshioka

1. Superior orbital fissure
2. Inferior orbital fissure
3. Infraorbital groove
4. Infraorbital canal
5. Infraorbital foramen
6. Lacrimal gland
7. Lacrimal nerve
8. Infraorbital nerve
9. Zygomatic nerve
10. Zygomaticotemporal nerve
11. Zygomaticofacial nerve
12. Communicating branch (parasympathetics)

