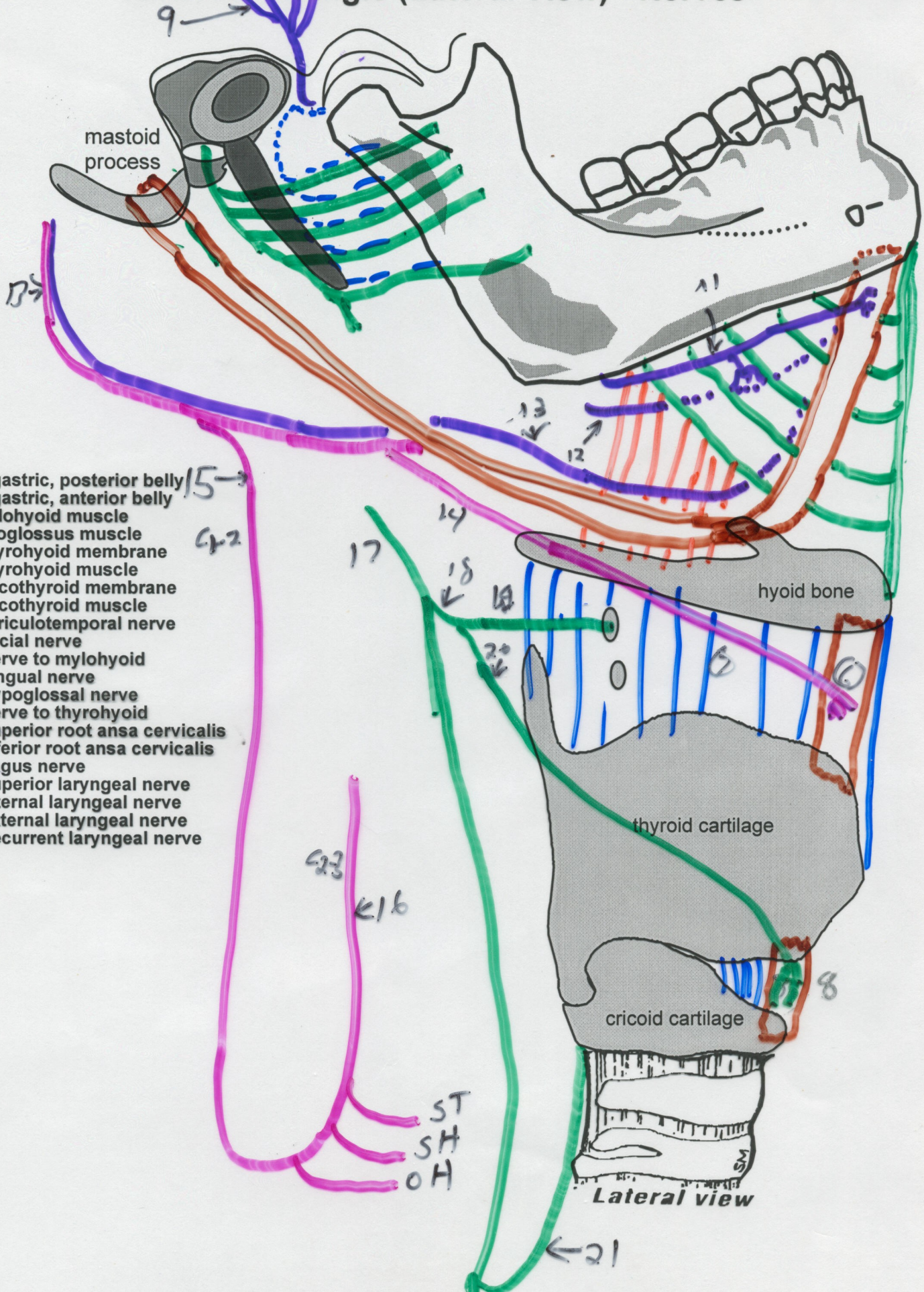


Anterior Triangle (Lateral View) - Nerves



- 15 → Digastric, posterior belly
- 16 → Digastric, anterior belly
- 17 → Mylohyoid muscle
- 18 → Hyoglossus muscle
- 19 → Thyrohyoid membrane
- 20 → Thyrohyoid muscle
- 21 → Cricothyroid membrane
- 22 → Cricothyroid muscle
- 23 → Auriculotemporal nerve
- 0 → Facial nerve
- 1 → Nerve to mylohyoid
- 2 → Lingual nerve
- 3 → Hypoglossal nerve
- 4 → Nerve to thyrohyoid
- 5 → Superior root ansa cervicalis
- 6 → Inferior root ansa cervicalis
- 7 → Vagus nerve
- 8 → Superior laryngeal nerve
- 9 → Internal laryngeal nerve
- 10 → External laryngeal nerve
- 11 → Recurrent laryngeal nerve

Lateral view