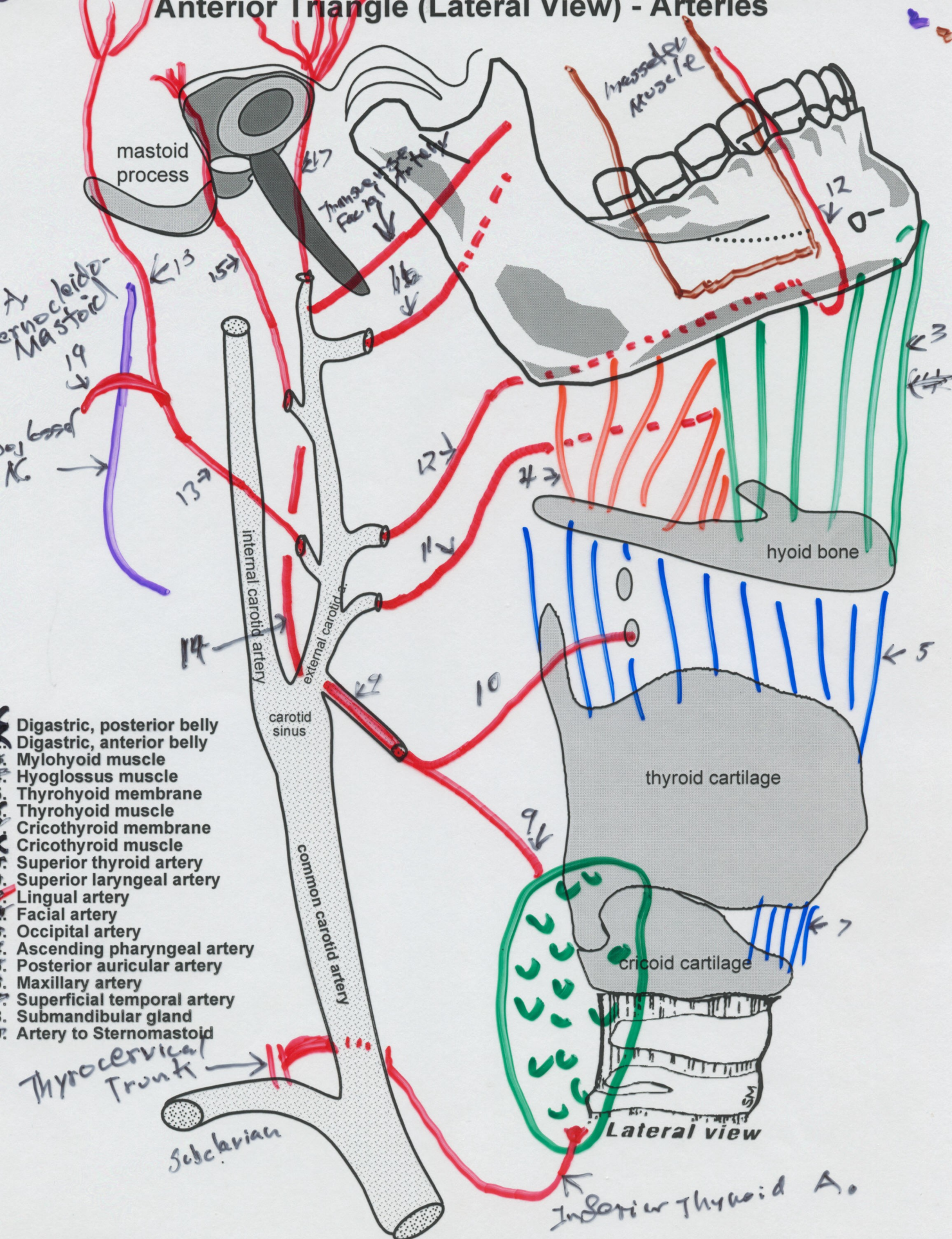


Anterior Triangle (Lateral View) - Arteries



- 1. Digastric, posterior belly
- 2. Digastric, anterior belly
- 3. Mylohyoid muscle
- 4. Hyoglossus muscle
- 5. Thyrohyoid membrane
- 6. Thyrohyoid muscle
- 7. Cricothyroid membrane
- 8. Cricothyroid muscle
- 9. Superior thyroid artery
- 10. Superior laryngeal artery
- 11. Lingual artery
- 12. Facial artery
- 13. Occipital artery
- 14. Ascending pharyngeal artery
- 15. Posterior auricular artery
- 16. Maxillary artery
- 17. Superficial temporal artery
- 18. Submandibular gland
- 19. Artery to Sternomastoid

Thyrocervical Trunk

Subclavian

Masseter Muscle

mastoid process

Innervation of Face

hyoid bone

thyroid cartilage

cricoid cartilage

Lateral view

Inferior Thyroid A.

internal carotid artery

external carotid a.

carotid sinus

common carotid artery

5

3

12

12

11

10

9

14

13

15

19

Arteriole to Mastoid

Artery to Sternomastoid