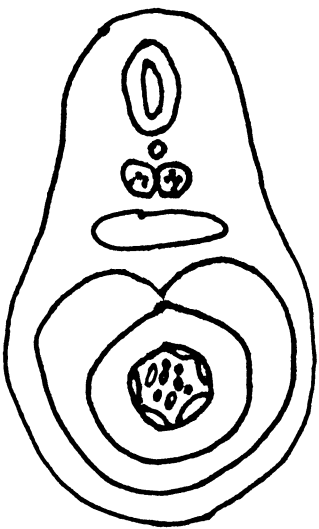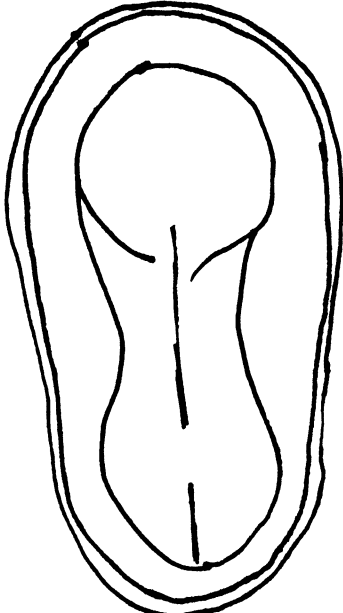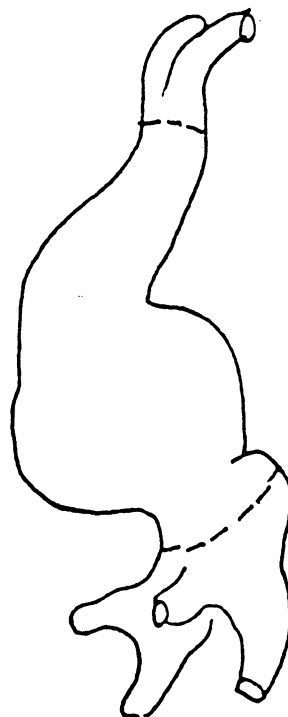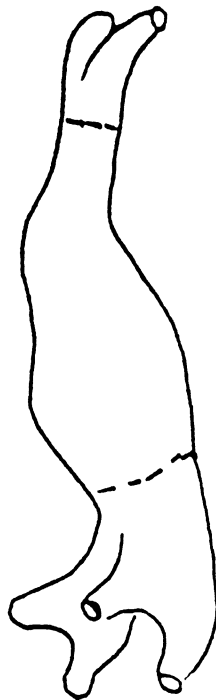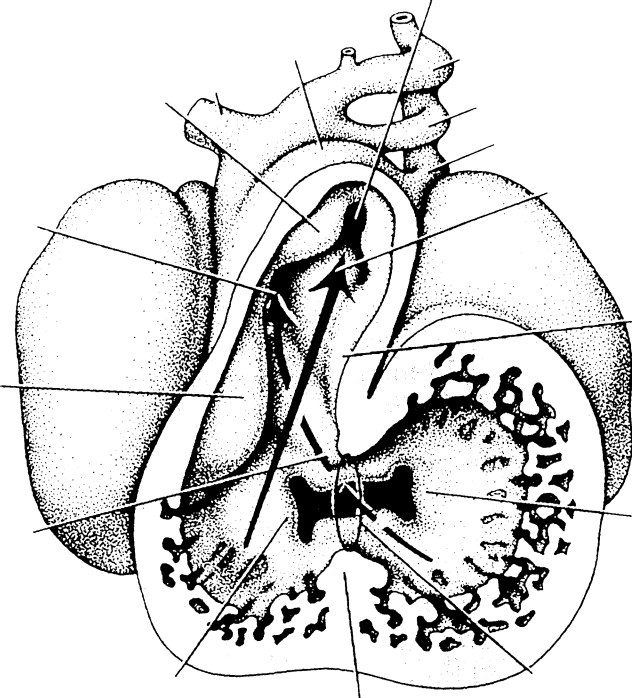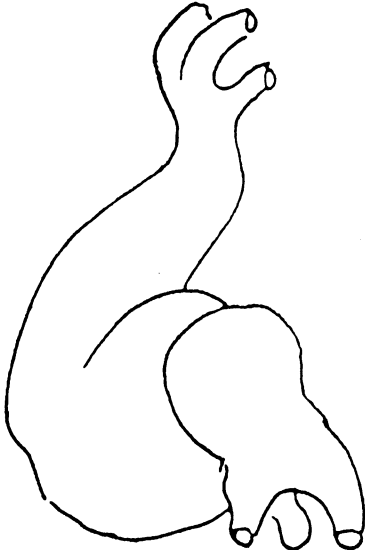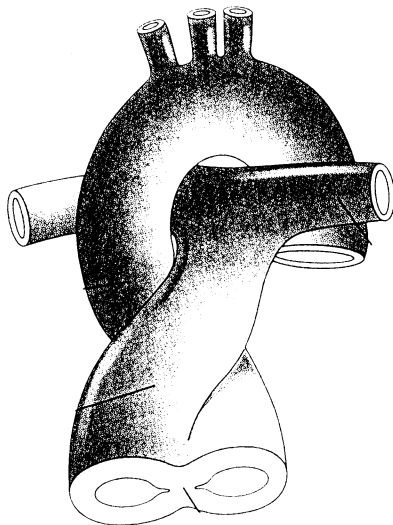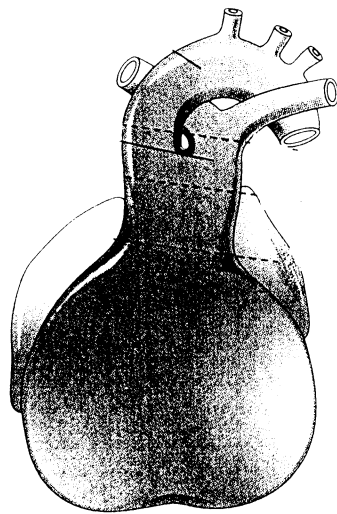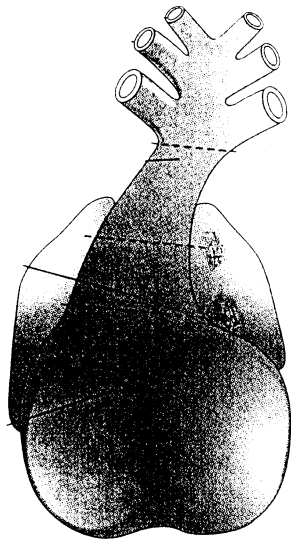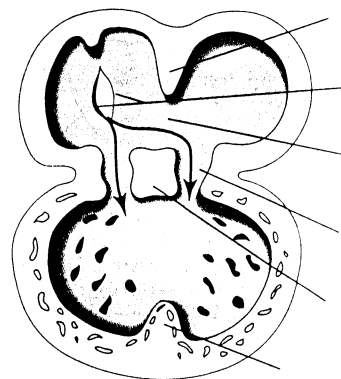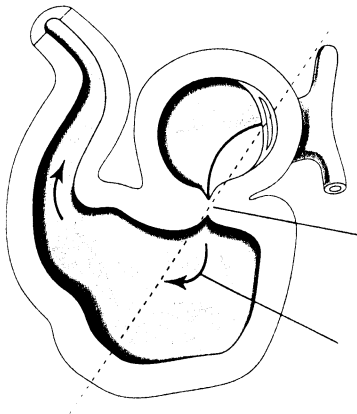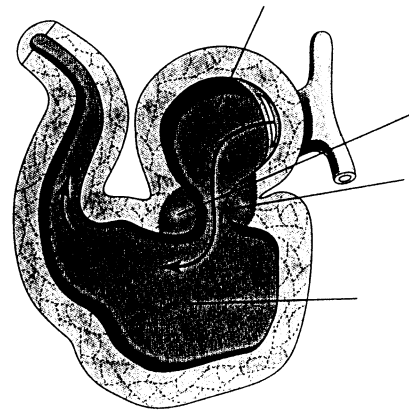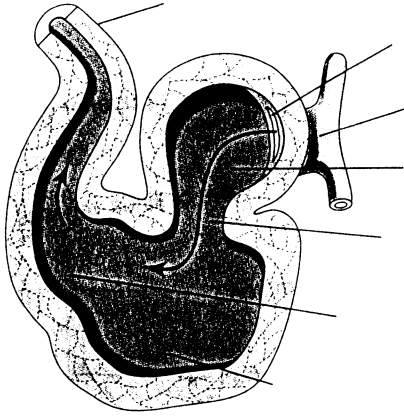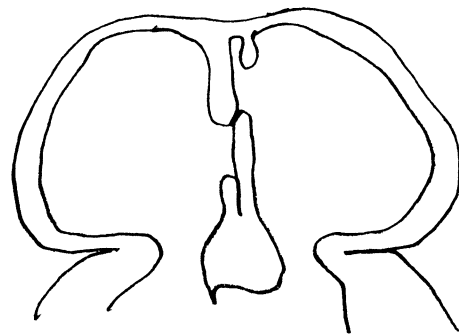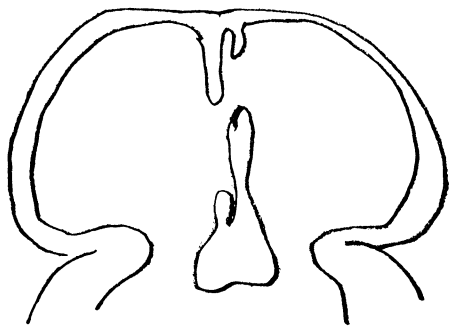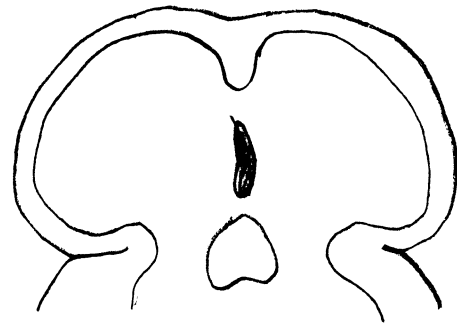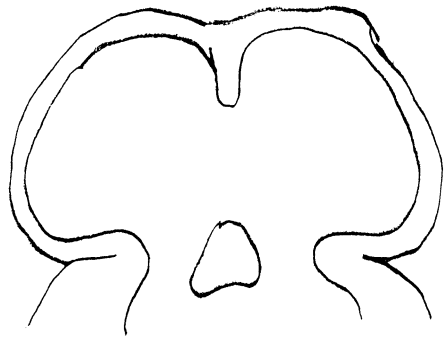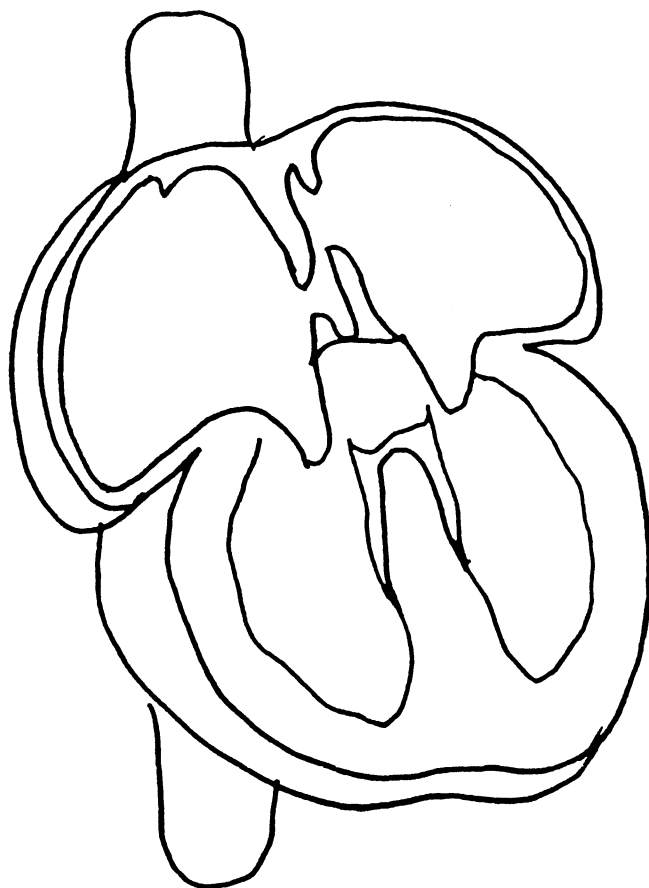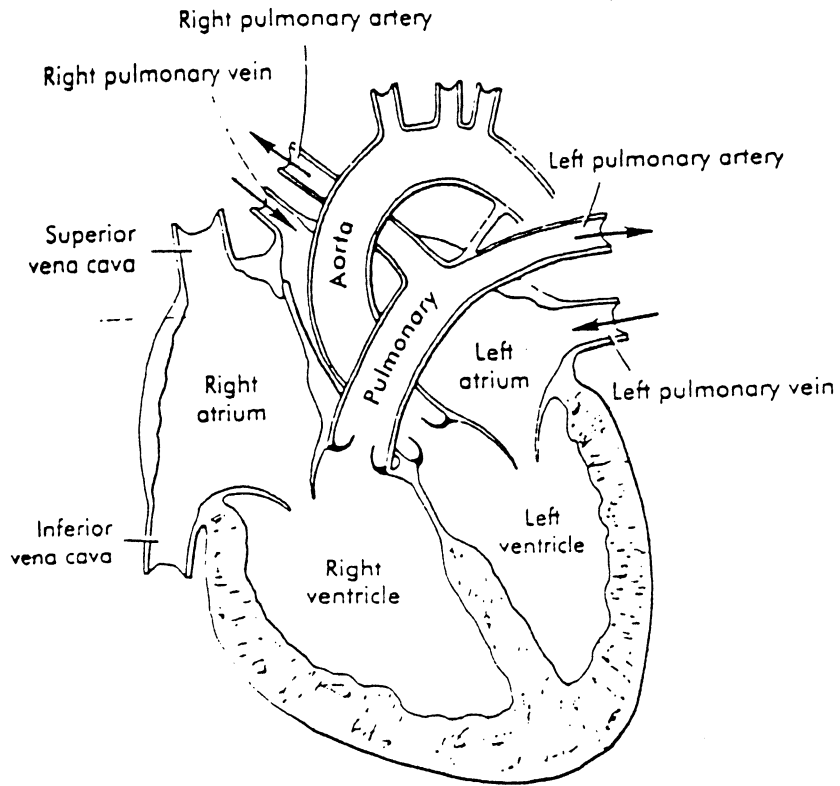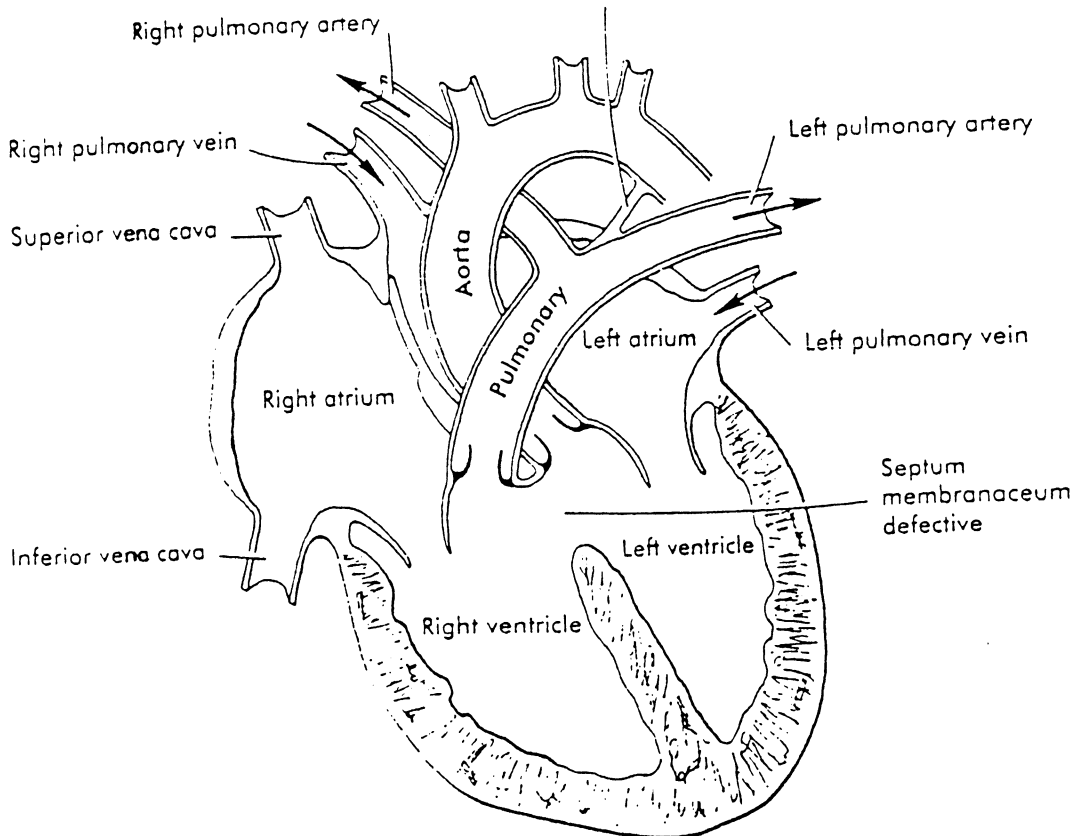


Normal heart

Ligamentum arteriosum



Interventricular Septal Defects.