

**STRUCTURAL BASIS OF MEDICAL PRACTICE
EXAMINATION 3**

September 13, 2012

PART I. Answer in the space provided. (12 pts)

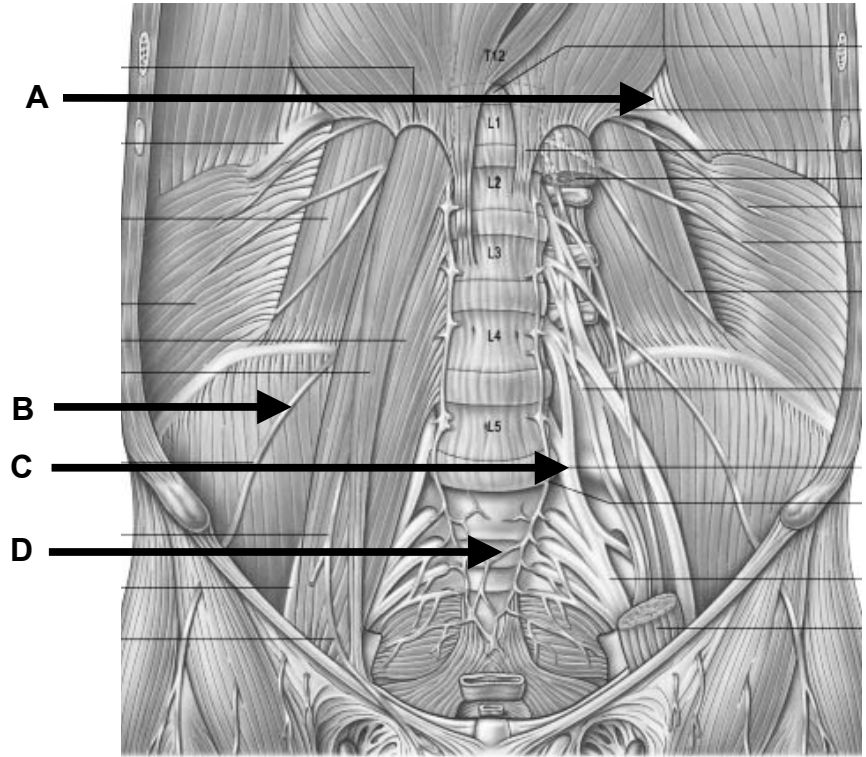
1. Identify the structures. (2 pts)

A. _____

B. _____

C. _____

D. _____



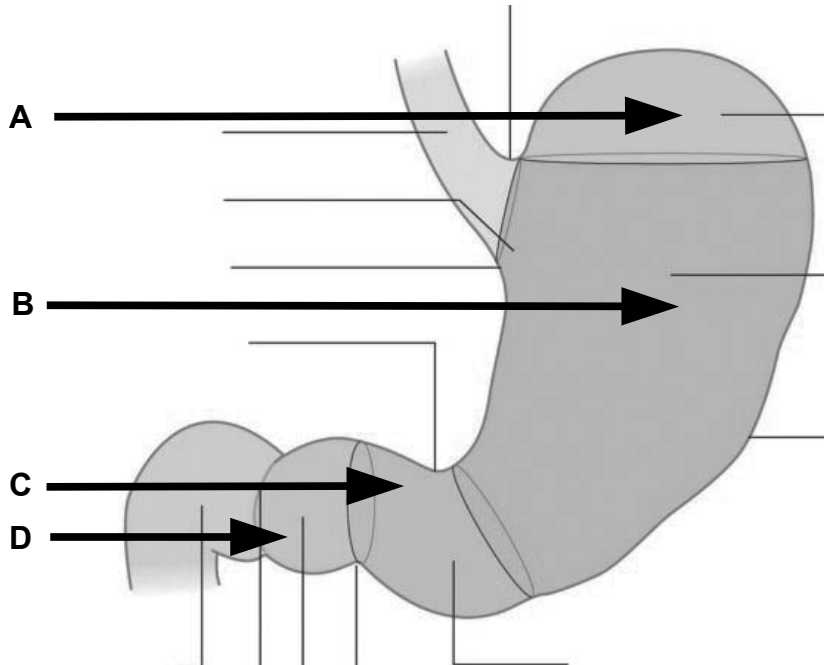
2. Identify the regions. (2 pts)

A. _____

B. _____

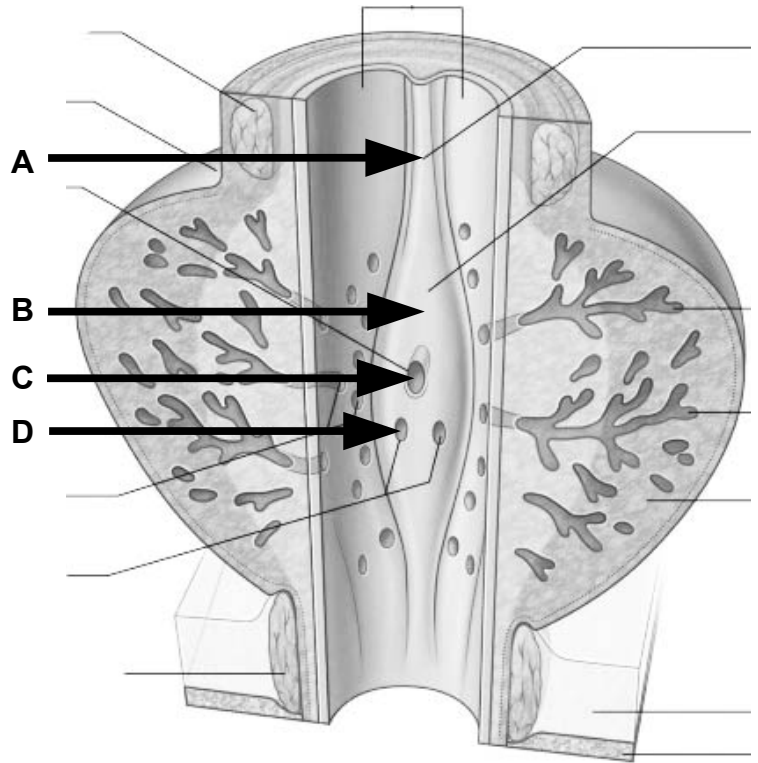
C. _____

D. _____



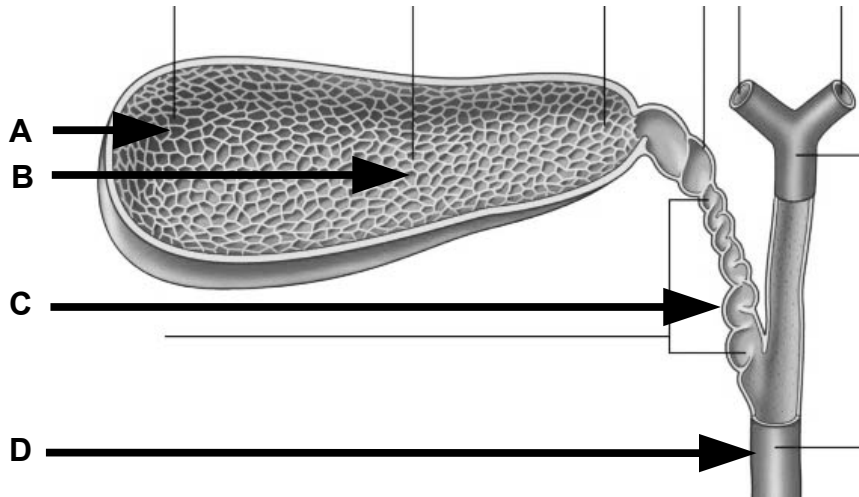
3. Identify the structures. (2 pts)

- A. _____
- B. _____
- C. _____
- D. _____



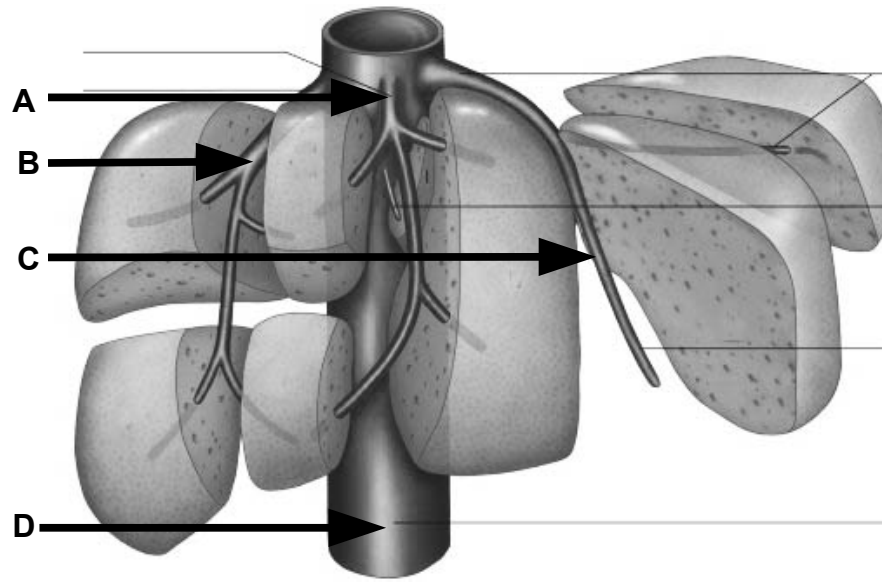
4. Identify the regions and structures. (2 pts)

- A. _____
- B. _____
- C. _____
- D. _____



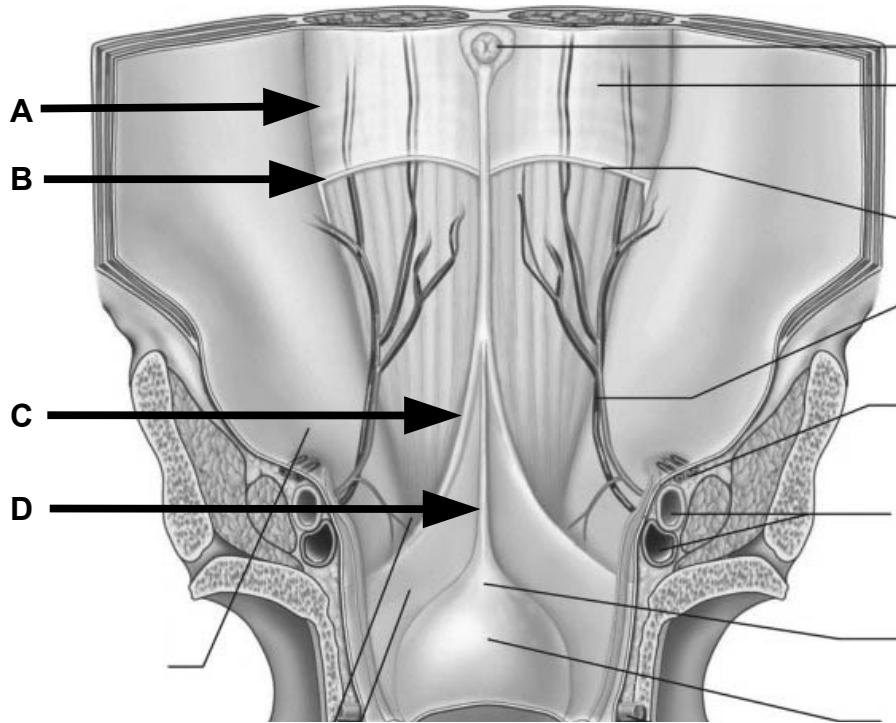
5. Identify the vessels. (2 pts)

- A. _____
- B. _____
- C. _____
- D. _____



6. Identify the structures. (2 pts)

- A. _____
- B. _____
- C. _____
- D. _____



Part II. Circle the correct answer. All, none, or some may apply. (18 pts)

1. With regard to anterior abdominal wall and inguinal canal:
 - a) The umbilicus vertebral projection is to T10 and the cutaneous innervation is by the L3 spinal nerve.
 - b) The aponeurosis of the internal oblique, inferior to the arcuate line, contributes to the anterior and posterior walls of the rectus sheath.
 - c) The linea semilunaris outlines the lateral margin of the rectus sheath.
 - d) Caput Medusae may lead to distension of the superficial circumflex iliac vein.
 - e) Scarpa's fascia takes on skeletal muscle as it transitions into Dartos fascia.
 - f) The obliterated umbilical artery creates a fold of peritoneum named the medial umbilical fold.

2. With regard to the peritoneal cavity:
 - a) Transversalis fascia lines the abdominal cavity and peritoneum lines the peritoneal cavity.
 - b) In the male, under non-pathological conditions, the peritoneal cavity is empty except for a film of serous fluid.
 - c) A swelling of the alimentary canal becomes the stomach and a diverticulum of the alimentary canal becomes the spleen.
 - d) The epiploic foramen provides a communication between the abdominal cavity and the peritoneal cavity.
 - e) The lesser curvature of the stomach has reflections of original ventral mesentery.
 - f) The tail of the pancreas together with the splenic artery, may become intraperitoneal within the gastrosplenic ligament.

3. With regard to the abdominal vasculature and the posterior abdominal wall:
 - a) There are five lumbar vertebrae and five pairs of lumbar arteries.
 - b) The superior anterior and posterior pancreaticoduodenal arteries anastomose with the second jejunal artery.
 - c) The vasa recta are shorter at the ileum and longer at the jejunum.
 - d) Blood from the portal system normally passes through the spleen before draining into the inferior vena cava.
 - e) Portacaval shunts include a pathway from the left gastric vein to the esophageal veins.
 - f) Swelling of the renal pelvis is accommodated by pararenal fascia.
 - g) The most distal extent along the alimentary canal where inhibition of peristalsis is driven by the superior mesenteric ganglion is along the right transverse colon.

4. With regard to the pelvic viscera:
- a) The ejaculatory duct enters the posterior wall of the membranous urethra.
 - b) Parietal pelvic fascia is an extension of the transversalis fascia into the pelvic cavity.
 - c) Passing along the superior margin of the lateral cervical ligament is the cervical artery.
 - d) An anastomosis between the internal and external iliac arteries occurs in the iliac fossa.
5. With regard to the perineum:
- a) The venous drainage of the rectum is partly to the portal system and partly to the caval system.
 - b) The puborectalis muscle attaches to the anococcygeal raphe and, thus, is tethered to the coccyx.
 - c) The bulbourethral glands drain into the membranous urethra.
 - d) The pectinate line is located at the inferior margin of the anal valves.
 - e) The pudendal nerve typically elaborates the inferior rectal nerve immediately proximal to the entrance of the pudendal canal.
 - f) The distal opening of the pudendal canal is at the level of the transverse perineal ligament.
6. With regard to the pelvic floor, nerves, and vessels:
- a) The ischiococcygeus (coccygeus) takes origin, in part, from the internal surface of the sacrospinous ligament.
 - b) Spinal cord levels S2-4 elaborate somatic and autonomic nerves that act together to mediate urination, defecation, and ejaculation.
 - c) Sympathetic nerves dilate the helicine arteries.
 - d) The sympathetic supply to the descending colon is by an arterial plexus and the parasympathetic supply is by a retroperitoneal path along the medial margin of the ascending colon.
 - e) Sectioning of the hypogastric nerves removes all sympathetic supply to the uterus.
 - f) The bulbospongiosus and the ischiocavernosus muscles are controlled by the autonomic nervous system.
 - g) The cerebral release mechanism for urination is mostly driven by the somatic nervous system.

Part III. Questions for Clinical Correlations. (4 pts)

1. A 35 year old female undergoes a laparoscopic cholecystectomy for intermittent episodes of cholecystitis due to gall stones. Two weeks after the procedure she returns to the surgeon complaining of right upper quadrant pain and “turning yellow.” On exam, her temperature = 100.5 F. She has healing laparoscopy port incisions without signs of infection. Her abdominal exam shows right upper quadrant tenderness and a mildly enlarged liver. She is obviously jaundiced. Her labs show elevated bilirubin levels and normal levels of pancreatic enzymes. You suspect a retained gall stone.

Which of the following location (s) would you most likely expect the stone to be in this patient?

- a. In the stump of the retained cystic duct
 - b. In the common hepatic duct
 - c. In the common bile duct
 - d. At the junction of the common bile duct and pancreatic duct
 - e. Any of the above locations would cause this patient’s signs and symptoms
2. A 45 year old morbidly obese male undergoes gastric bypass surgery by a laparoscopic approach. During the procedure, the cardia of the stomach is maintained as the site for food storage and passage. While performing the bypass, the left gastric artery is lacerated and must be ligated at its origin.

In order to maintain an adequate blood supply to the cardia, which of the following arteries would most likely supply this collateral blood supply?

- a. Gastroduodenal
 - b. Superior mesenteric
 - c. Left hepatic
 - d. Right gastric
 - e. Right gastro-omental (gastroepiploic)
3. A 42 year old female presents to her gynecologist with complaints of irregular menses and left lower quadrant pain. On exam, her vital signs are stable. Pelvic exam reveals a left adnexal mass. A vaginal ultrasound confirms a soft tissue mass in the proximity of the left ovary and ampulla of the left uterine tube. Laparoscopic surgery is performed and during the removal of the ovary and associated uterine tube there is persistent arterial bleeding noted, in spite of ligation of the uterine artery.

Which of the following structures should also be ligated in order to control this arterial bleeding?

- a. Round ligament of the uterus
- b. Suspensory ligament of the ovary
- c. Cardinal ligament
- d. Broad ligament of the uterus

4. A 29 year old male is involved in a bar fight and sustains a knife wound to his right costovertebral angle. On exam, he is pale, lethargic, heart rate = 130 b.p.m. and blood pressure of 70/30. His abdomen is rigid. The knife wound is oozing blood. A CT scan is performed showing blood in the retroperitoneum as well as the peritoneum. An exploratory laparotomy is performed and a right nephrectomy results due to excessive arterial bleeding from the organ. During the procedure, the right renal artery and vein are ligated at their origin. The right suprarenal (adrenal) gland is maintained.

Given the loss of the right renal artery, which of the following arteries will most likely maintain a blood supply to the right suprarenal (adrenal) gland?

- a. Inferior phrenic
- b. Ureteral
- c. Celiac
- d. Testicular
- e. Common hepatic

Part IV. Indicate your understanding of the following. Answer in the space provided. (30 pts)

1. Endoscopic procedures aimed at the vermiform appendix carry the risk of misidentifying the location of the vermiform appendix. **Provide a developmental account for the adult anatomy of the vermiform appendix. (6 pts)**

2. Diseases of the head of the pancreas may seriously damage surrounding structures. **Provide a developmental account for the adult anatomy of the head of the pancreas. (6 pts)**

3. Catheterization of the urethra may go awry at the membranous urethra and cause urine to extravasate into the potential space defined by the attachments of Scarpa's fascia. **Define the relationships of fluids accumulating in the potential space defined by Scarpa's fascia and derivatives. (6 pts)**

4. Erectile dysfunction is characterized by the inability to develop or maintain an erection during sexual performance. **Discuss the anatomy and function of pelvic splanchnic nerves in the erection of either the clitoris or the penis. (6 pts)**

5. The seemingly unrelated symptoms of nausea, flank pain, changes in facial hair, and scrotal swelling may, in fact, be related. **Discuss relationships and blockages of the left renal vein. (6 pts)**

Part V. Answer in the space provided. Include the back of each page if required). (36 pts)

- 1. A hysterosalpingogram determines patency of the uterine ostia and uterine tubes. Radiographic contrast is injected into the uterine cavity through the vagina and cervix. If the fallopian tubes are patent, dye fills spills into the abdominal cavity. Blockages are then ruled out as the cause of a patient's infertility. **Indicate your understanding of the uterus, uterine tubes, and ovary as to structure, orientation, relationships (anterior, posterior, superior, inferior, medial, lateral), ligamentous support, peritoneal associations, innervation (preganglionic, postganglionic, and visceral afferent pathways), vasculature, and lymphatics. (12 pts)****

EXAM NUMBER _____

EXAM NUMBER _____

2. Indirect inguinal hernias result from a patent processus vaginalis. Abdominal viscera may move through the processus vaginalis into the scrotum. **Review the anatomy of the spermatic cord. Include contents, coverings, fascial boundaries, innervation, vasculature, lymphatics, and relationships. Discuss the pathway and location of an indirect inguinal hernia that has descended into the scrotum. (12 pts)**

EXAM NUMBER _____

EXAM NUMBER _____

3. Peptic ulcer disease may erode the posterior wall of the stomach and spill stomach contents into the lesser sac. **Define the boundaries (including spaces and/or recesses) of the lesser sac. Account for dull pain followed by sharp pain when the posterior stomach wall perforates. Discuss the pathway of spilled stomach contents that pass from the lesser sac into the greater sac, and the location of these contents with respect to body position. (12 pts)**

EXAM NUMBER _____

EXAM NUMBER _____